50th Annual SENRS Meeting | Interesting Case Electronic Exhibit

Combined Diagnostic Methods Uncover a High Grade Glioma Masquerading as Low Grade

A Novel High-Grade Glioma with Pleomorphic and Pseudopapillary (HPAP) Case in Li Fraumeni Syndrome

Tamana Gill BS, Nyra Ahmed BMLSc, Taiylor Renae BS, Caroline Goldin MD, Vani Vijayakumar MD

[University of Queensland, Ochsner Clinical School of Medicine]

Clinical Presentation

24

year-old woman

Family history of Li-Fraumeni syndrome (germline TP53)

1

Presentation

Seizure-like episode with visual aura, right arm weakness, and loss of consciousness, followed by a motor vehicle accident

2

CT head

Enhancing hyperdense left occipital lesion, initially concerning for a cavernous malformation

3

MRI brain

Features more consistent with a neoplastic process than a vascular lesion

4

Next step

Resection of the mass with further molecular analysis

Imaging Findings

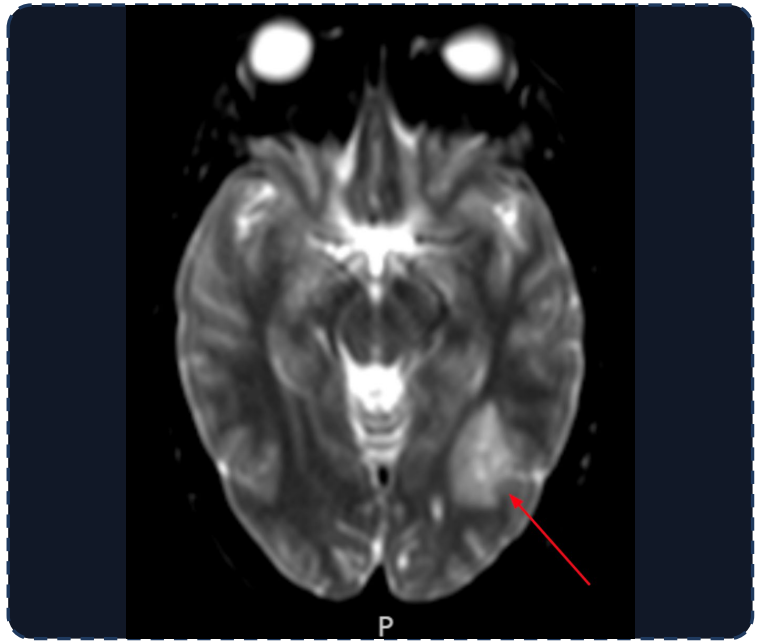

DWI (pre-treatment)

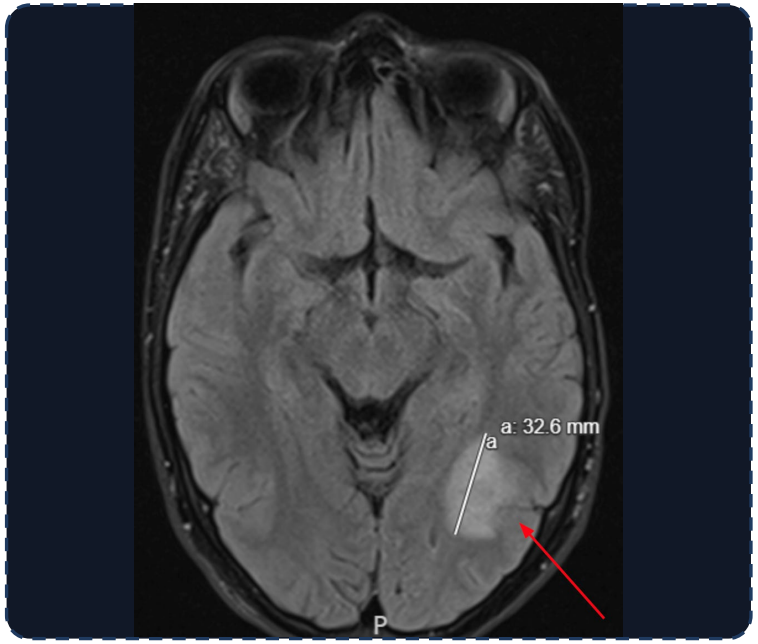

T2 FLAIR (pre-treatment)

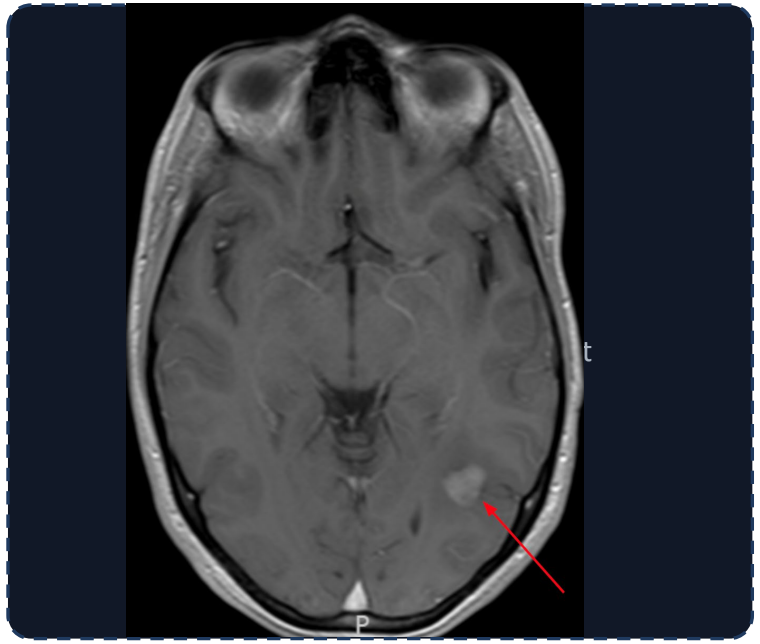

T1 post-contrast (pre-treatment)

1.4 × 1.3 cm

Solitary, cortically based enhancing lesion, left occipital lobe

3.3 cm

Surrounding vasogenic edema

Restricted

Diffusion restriction within the lesion

Imaging Discussion: Differential Diagnosis

Highest concern: neoplasm

- Glioma
- Lymphoma
- Metastasis

Widened by cortical location and young age

- Polymorphous low-grade neuroepithelial tumor of the young
- Ganglioglioma
- Dysembryoplastic neuroepithelial tumor
- **Pleomorphic xanthoastrocytoma (PXA)**

PXA, on the differential from the outset, later became the leading histologic impression.

Management

1

Resection

Left occipital craniotomy with gross total resection

2

Histology / IHC

CD34 negative, IDH1 wild type, ATRX retained. Favored a low-grade glial neoplasm, specifically PXA

3

Targeted NGS

TP53 and NF1 mutations with monosomy 13

Integrated diagnosis

High-grade glioma with pleomorphic and pseudopapillary features (HPAP)

- Unclassified entity first described in 2023
- One of the first reported cases arising with germline TP53 mutation (Li-Fraumeni syndrome)
- Suggests a possible link between constitutional TP53 loss and this emerging tumor class

Outcome

No residual disease

Postoperative and 3-month MRI: no residual or recurrent enhancing disease

Residual deficits

Gait and fine motor deficits

Surveillance

Molecular risk-adapted surveillance imaging planned

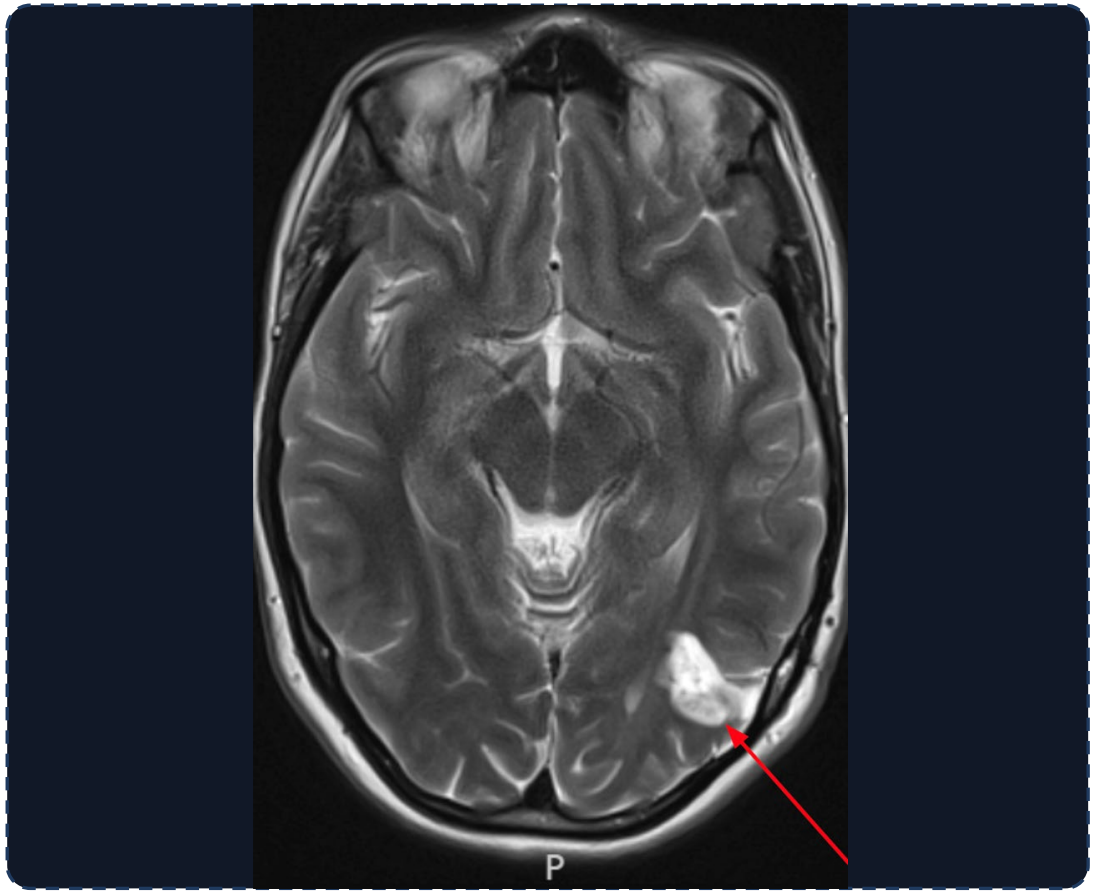

T2 post-contrast, 6-month follow-up

Take Home Points

Imaging

Small, cortically based enhancing lesion suggested lower grade

Histology / IHC

Pattern suggestive of PXA

Molecular

TP53 and NF1 mutations with monosomy 13 unmasked HPAP

Glioma grading cannot rest on any single data stream.

Benign-appearing, cortically based enhancing lesions, especially in patients with cancer predisposition syndromes, can harbor aggressive molecular signatures and should prompt early NGS-based integrated diagnosis rather than reassurance from imaging or histology alone.

Disclosure: AI-assisted writing tools (Claude, Anthropic) were used in drafting and editing this abstract. All clinical content, data, and conclusions were reviewed and verified by the authors.