Rheumatoid Meningitis as a Rare Stroke Mimic: A Radiology Case Report

Authors:
Spencer Waldman, MD, Yehuda Herman and Paul K. Lee, MD.
Affiliation:
Zucker School of Medicine at Hofstra/Northwell

Background

- Rheumatoid meningitis (RM) is a rare extra-articular manifestation of rheumatoid arthritis (RA) that may present with transient focal neurologic deficits, seizures, headache, or encephalopathy, often mimicking acute ischemic stroke. Because its MRI findings overlap with infectious, inflammatory, and neoplastic disorders, diagnosis remains challenging and requires a high index of suspicion.[1–3]

Case Presentation

- A 66-year-old woman with longstanding seropositive RA treated with multiple disease-modifying antirheumatic drugs presented with recurrent transient neurologic deficits, including left hand weakness followed by expressive aphasia. MRI demonstrated multifocal cortical restricted diffusion involving multiple vascular territories with associated cortical FLAIR hyperintensity. Post-contrast imaging demonstrated diffuse pachymeningeal thickening and linear and nodular leptomeningeal enhancement over the cerebral convexities. Given the patient's history of RA, the imaging findings raised suspicion for rheumatoid meningitis while maintaining a broad differential diagnosis including leptomeningeal carcinomatosis, primary CNS lymphoma, neurosarcoidosis, infectious meningitis, and other inflammatory pachymeningitides. Cerebrospinal fluid studies and cytology were nondiagnostic. Meningeal biopsy subsequently confirmed chronic inflammatory meningitis consistent with rheumatoid meningitis.

Conclusion

- Diffuse pachymeningeal and leptomeningeal enhancement accompanied by multifocal cortical diffusion restriction should prompt consideration of rheumatoid meningitis in patients with a history of rheumatoid arthritis. Although the imaging appearance encompasses a broad differential diagnosis—including leptomeningeal carcinomatosis, lymphoma, neurosarcoidosis, infectious meningitis, and other inflammatory disorders—recognition of this characteristic pattern can appropriately raise clinical suspicion and expedite definitive diagnosis through meningeal biopsy, ultimately facilitating timely immunosuppressive therapy

Figure 1: Clockwise from top left: Axial post contrast T1 image demonstrates diffuse pachymenigeal enhancement. Axial post contrast T1 at the superior convexity demonstrates leptomeningeal enhancement in the left frontal lobe. Axial DWI sequences demonstrate abnormal areas of restricted cortical diffusion in the left superior parietal lobule, bilateral posterior insular areas, left occipital lobe, and questionably along the anterior cingulate cortex.

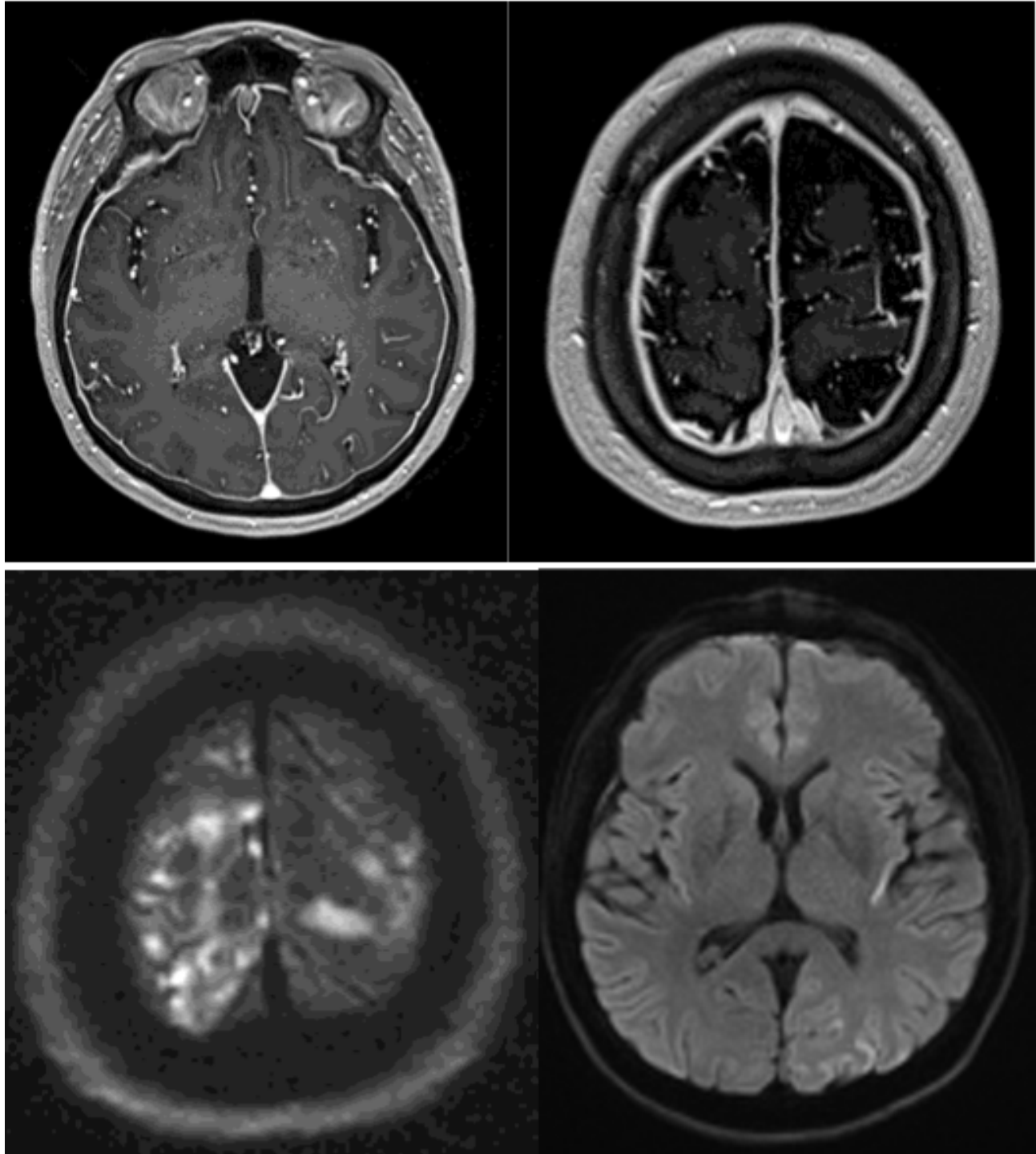

References

- 1. Villa E, Sarquis T, de Grazia J, et al. Rheumatoid meningitis: A systematic review and meta-analysis. Eur J Neurol. 2021;28(9):3201-3210. doi:10.1111/ene.14904. Wiley Online Library
- 2. Qin Z, Kim J, Valencia D, et al. Rheumatoid meningitis: A case report and review of the literature. Neurol Clin Pract. 2020;10(1):73-83. doi:10.1212/CPJ.0000000000000678. American Academy of Neurology
- 3. Schuster S, Braass H, Iking-Konert C, et al. Rheumatoid meningitis: A rare cause of aseptic meningitis with frequently stroke-like episodes. Neurol Clin Pract. 2018;8(5):451-455. doi:10.1212/CPJ.0000000000000504. American Academy of Neurology
- 4. Lattanzi S, Cagnetti C, Foschi N, et al. Leptomeningeal inflammation in rheumatoid arthritis. Neurol Neuroimmunol Neuroinflamm. 2014;1(4):e43. doi:10.1212/NXI.0000000000000043.