Interval Development of an Intracranial Mass in Acute Myeloid Leukemia: A Diagnostic Imaging Dilemma



Shaneily Colon Morera, MS4

Universidad Central del Caribe School of Medicine



Alejandro Arbona - Lampaya, MS4

Universidad de Puerto Rico School of Medicine



Cameron Henry, MD

Vanderbilt University Medical Center

Clinical Presentation

- 71-year-old woman presenting after a witnessed seizure.

2023 — Atypical temporal meningioma → left frontotemporal craniotomy

2024 — AML → hematopoietic stem cell transplant

Subsequently off chemotherapy

2025 — Cerebrovascular accident

Key clinical point

Multiple competing causes of a left frontal lesion (hemorrhage into prior infarct, meningioma recurrence, leukemic relapse) — the diagnostic dilemma.

Imaging findings: CT wo Contrast



Figure 1.Axial non -contrast CT demonstrating a hyperattenuating left frontal masslike lesion.

Dilemma ⚠

Hemorrhage or hypercellular tumor?

The hyperattenuating appearance initially raised concern for hemorrhage into the region of prior infarction. However, the patient's history of AML prompted further evaluation with MRI.

Cao 2025; Meyer 2019.

Imaging findings: MRI

Initial Presentation

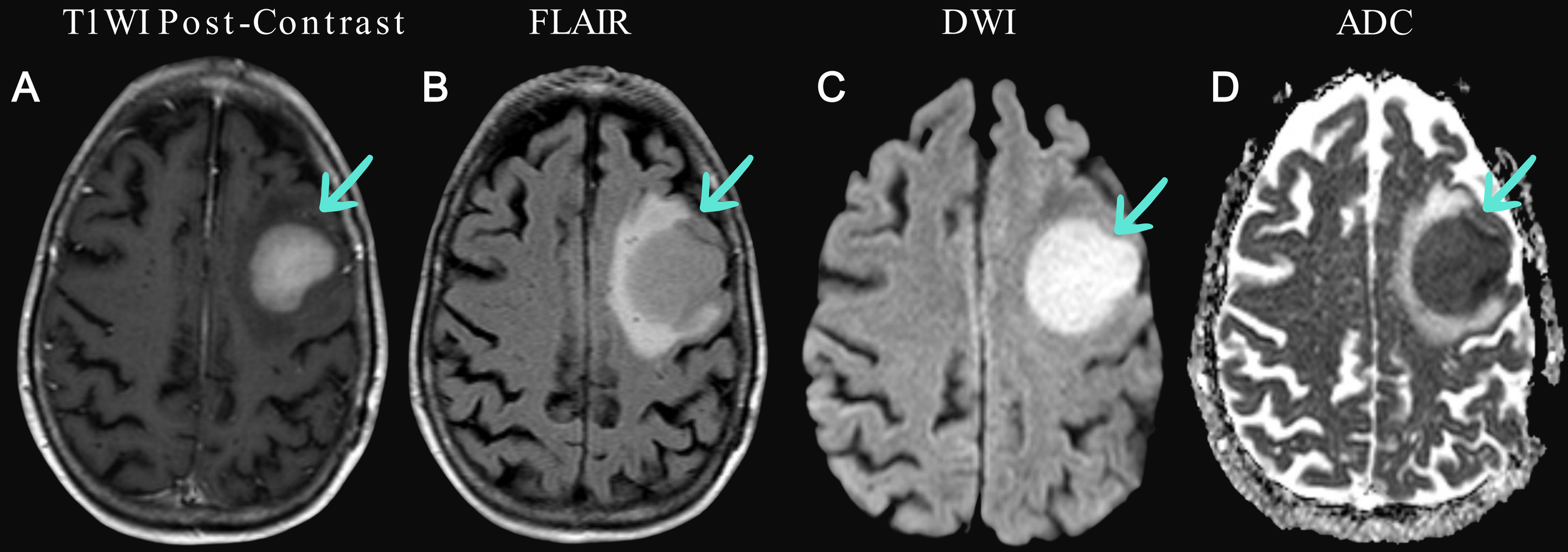

Figure 2. Axial brain MRI at initial presentation. Post -contrast T1WI (A) demonstrates a 3.2 × 3.2 cm avidly and homogeneously enhancing left frontal mass. FLAIR (B) shows surrounding vasogenic edema. DWI (C) demonstrates hyperintensity with corresponding low signal on the ADC map (D), consistent with restricted diffusion.

Hou 2017; Meyer 2019.

Imaging Discussion : Recognizing the Pattern

Intracranial myeloid sarcoma typically demonstrates features of a hypercellular mass.

Non-contrast CT



- Hyper-attenuating mass

T1WI (pre-contrast)

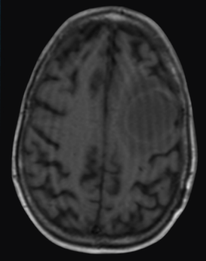

- Hypo to iso-intense relative to gray matter

T2/FLAIR

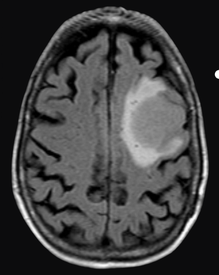

- Iso to mildly hyperintense with surrounding vasogenic edema

T1WI (post-contrast)

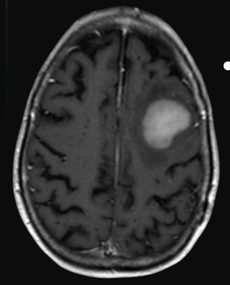

- Avid homogeneous enhancement

DWI/ADC

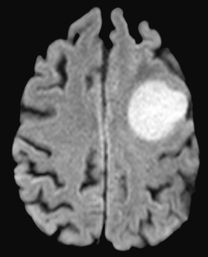

- Hyperintense signal within the lesion

DWI/ADC

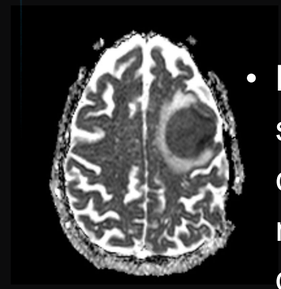

- Low ADC signal, confirming restricted diffusion

The combination of hyperattenuation on CT, avid homogeneous enhancement, restricted diffusion, and minimal susceptibility is characteristic of a hypercellular neoplasm and can help distinguish it from hemorrhage.

Additional features: Minimal necrosis and calcification. Restricted diffusion is reported in ~90 –96% of intracranial myeloid sarcomas.

Chaudhry 2015; Hou 2017.

Differential Diagnosis

KEY POINT: Imaging can narrow the differential, but substantial overlap remains. Clinical context and tissue or molecular confirmation are essential for definitive diagnosis.

Leukemic mass/Myeloid sarcoma

- Homogeneous enhancement
- Restricted diffusion
- Minimal susceptibility

Tip:

- History of AML should raise suspicion for CNS leukemic involvement.

CNS Lymphoma

- Homogeneous enhancement
- Marked diffusion restriction
- Can closely mimic a leukemic mass

Tip:

- A major imaging mimic; imaging alone may not reliably distinguish it from a leukemic mass.

High grade glioma

- More heterogeneous enhancement
- Necrosis/ring enhancement more typical
- Susceptibility may be present

Tip:

- Heterogeneity, necrosis, and intratumoral susceptibility favor high-grade glioma over a hypercellular hematologic mass.

Metastasis

- Variable enhancement
- May demonstrate necrosis
- Often prominent surrounding edema

Tip:

- Multiplicity and a known primary malignancy can favor metastases.

Chaudhry 2015; Chiu 2023; Kickingereder 2014; Achrol 2019.

Diagnostic Workup

Bone marrow biopsy

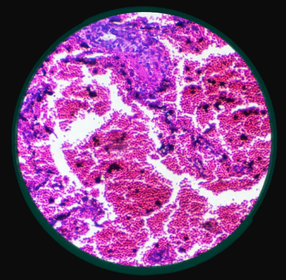

- No blasts
- 100% donor chimerism
- No mutations detected

No evidence of systemic marrow relapse

CSF Analysis



- Molecular evidence supporting CNS involvement by AML

FLT3-TKD Mutation Detected

Diagnostic Conclusion



- Despite negative bone marrow evaluation.

CNS Involvement by AML

NCCN AML v5.2026.

Management

Intrathecal Chemotherapy



- 3 day course

Systemic Therapy



- HiDAC (High dose cytarabine)
  +
  Gilteritinib

Craniospinal Radiation



- 12 fractions were completed around 3 months after initial imaging.

Management pearl: CNS/extramedullary AML requires multimodal therapy incorporating systemic and CNS -directed treatment, with radiation considered for bulky disease or mass -effect symptoms.

NCCN Guidelines: Acute Myeloid Leukemia, Version 5.2026.

Outcome/Treatment Response

Baseline

T1WI Post-Contrast

FLAIR

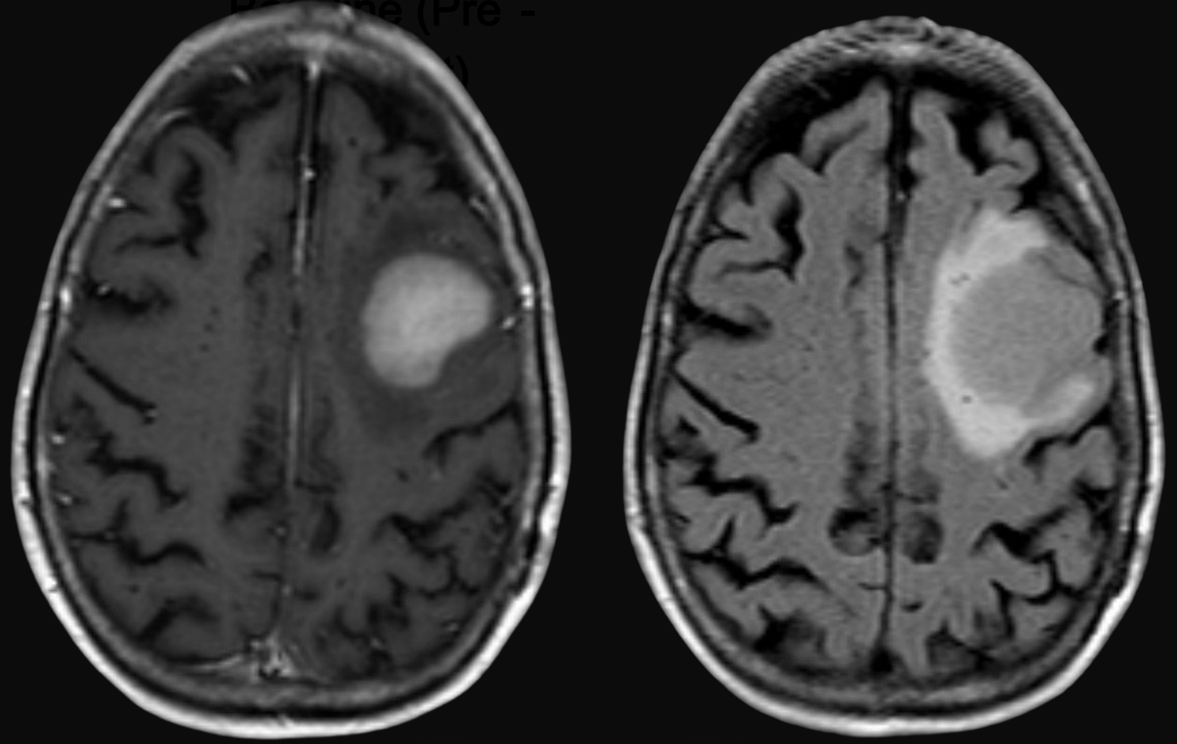

3.2 x 3.2 cm

4-month follow up

T1WI Post-Contrast

FLAIR

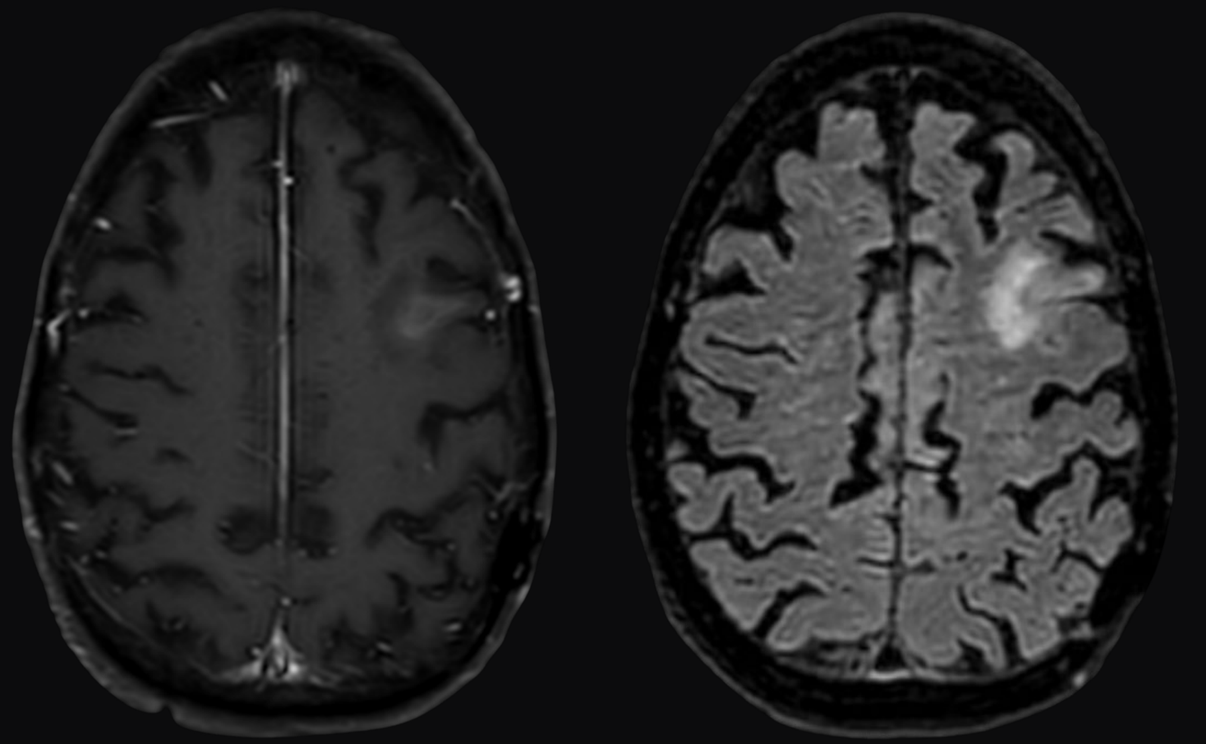

1.6 x 1.1 cm

The 3.2 × 3.2 cm enhancing left frontal mass with surrounding vasogenic edema decreased to 1.6 × 1.1 cm at 4-month follow-up, with increasingly ill-defined margins and mild residual edema.

Hou 2017.

Take Home Points

- Intracranial leukemic involvement should be considered when a new brain mass develops in a patient with treated AML, even without evidence of bone marrow relapse.
- Multiparametric MRI can help distinguish a hypercellular neoplasm from hemorrhage when CT hyperattenuation creates diagnostic uncertainty.
- Imaging findings are not specific. Significant overlap exists among leukemic masses, CNS lymphoma, high-grade glioma, and metastasis.
- Tissue, CSF, or molecular confirmation is essential when imaging alone cannot establish the diagnosis.
- Serial MRI is valuable for assessing treatment response.

Cao 2025; Hou 2017; NCCN AML v5.2026.

References

1. Cao Y, Cao P. Intracranial extramedullary relapse of acute myeloid leukemia presenting as myeloid sarcoma mimicking meningioma: a case report and literature review. Front Oncol. 2025.
2. Meyer HJ, Pönisch W, Schmidt SA, et al. Clinical and imaging features of myeloid sarcoma: a German multicenter study. BMC Cancer. 2019.
3. Hou X, Du L, Yu H, Zhang X. Use of magnetic resonance imaging for diagnosis and after treatment of patients with myeloid sarcoma of the brain. Oncotarget.2017.
4. National Comprehensive Cancer Network. NCCN Clinical Practice Guidelines in Oncology: Acute Myeloid Leukemia, Version 5.2026.
5. Chaudhry AA, Gul M, Chaudhry AA, Dunkin J. Qualitative assessment of diffusion-weighted imaging and susceptibility-weighted imaging of myeloid sarcoma involving the brain. J Comput Assist Tomogr. 2015.
6. Chiu AM, Yoon JG, Tirumani SH, Ramaiya NH, Smith DA. Myeloid sarcoma: a primer for radiologists. J Comput Assist Tomogr. 2023.
7. Kickingereder P, Wiestler B, Sahm F, et al. Primary central nervous system lymphoma and atypical glioblastoma: multiparametric differentiation by using diffusion-, perfusion-, and susceptibility-weighted MR imaging. Radiology.2014.
8. Achrol AS, Rennert RC, Anders C, et al. Brain metastases. Nat Rev Dis Primers.2019.