SENRS 50th Annual Meeting

Hypoglossal Nerve Palsy Secondary to Vertebral Artery Compression

October 17, 2026

Michael Gonzalez, BS | Bradford Mitchell, MD

Wake Forest School of Medicine

CharlotteRadiology



Clinical Presentation

Clinical Presentation

- 74M presents w/ 6mo hx of progressive **tongue dysfunction**
- Characterized by:
  - Intermittent tongue spasms
  - Right-sided tongue weakness
  - Impaired tongue mobility
  - Dysarthria
  - Mild dysphagia
  - Drooling
- Clinical exam demonstrated an **isolated right hypoglossal nerve (CN XII) palsy**



https://dmphysios.com/conditions-symptoms/hypoglossal-nerve-injury/



Imaging

Imaging

- Axial FIESTA MRI
- Both CN XIIs can be visualized (arrows)
- Right CN XII noted to be displaced by vertebral artery (VA) (arrowhead)

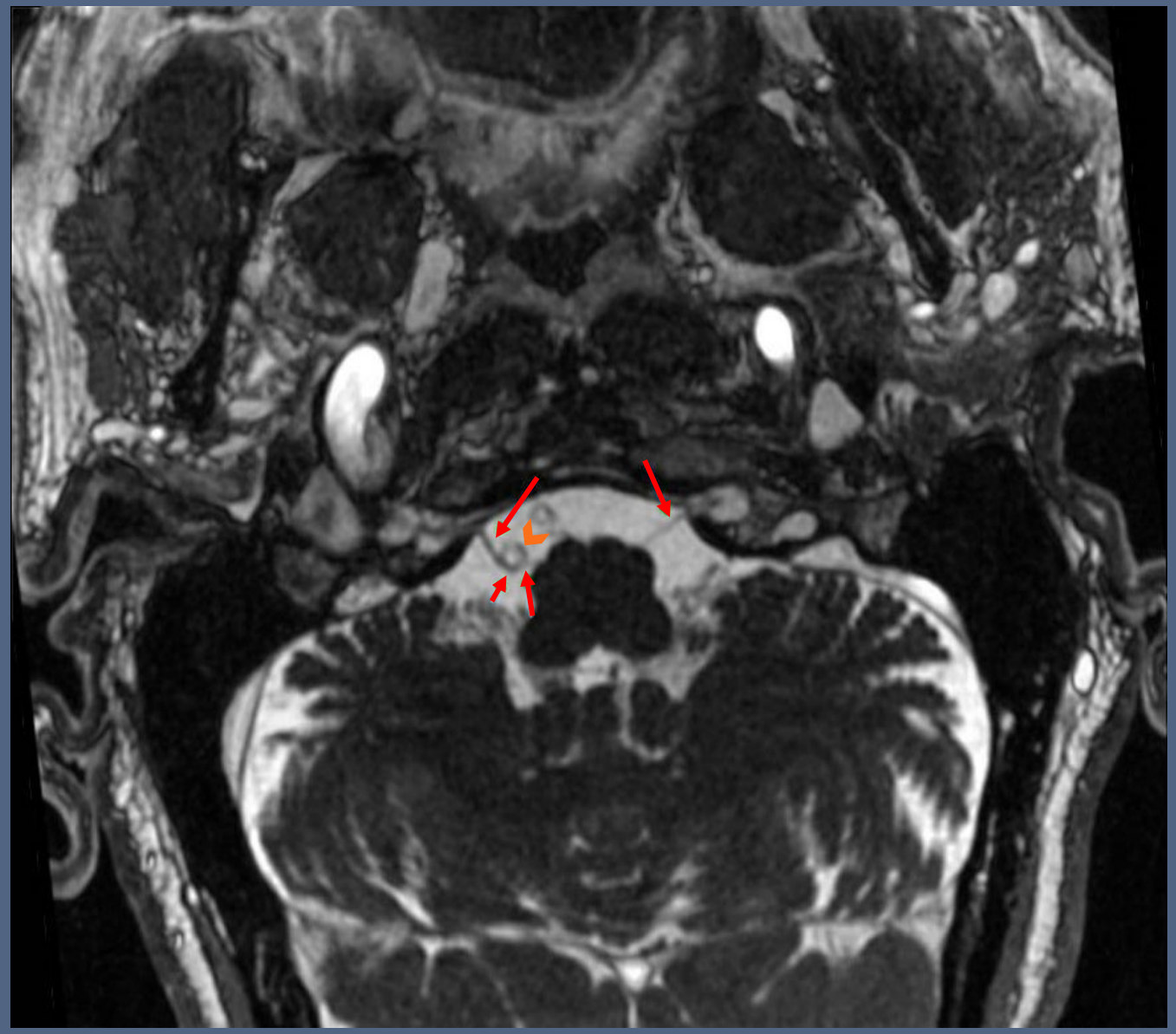


Management

Intraoperatively:

- VA observed to **displace & stretch** CN XII
- **Arterial pulsations** from VA noted
- These pulsations led **to repetitive movement** of CN XII **against** the VA

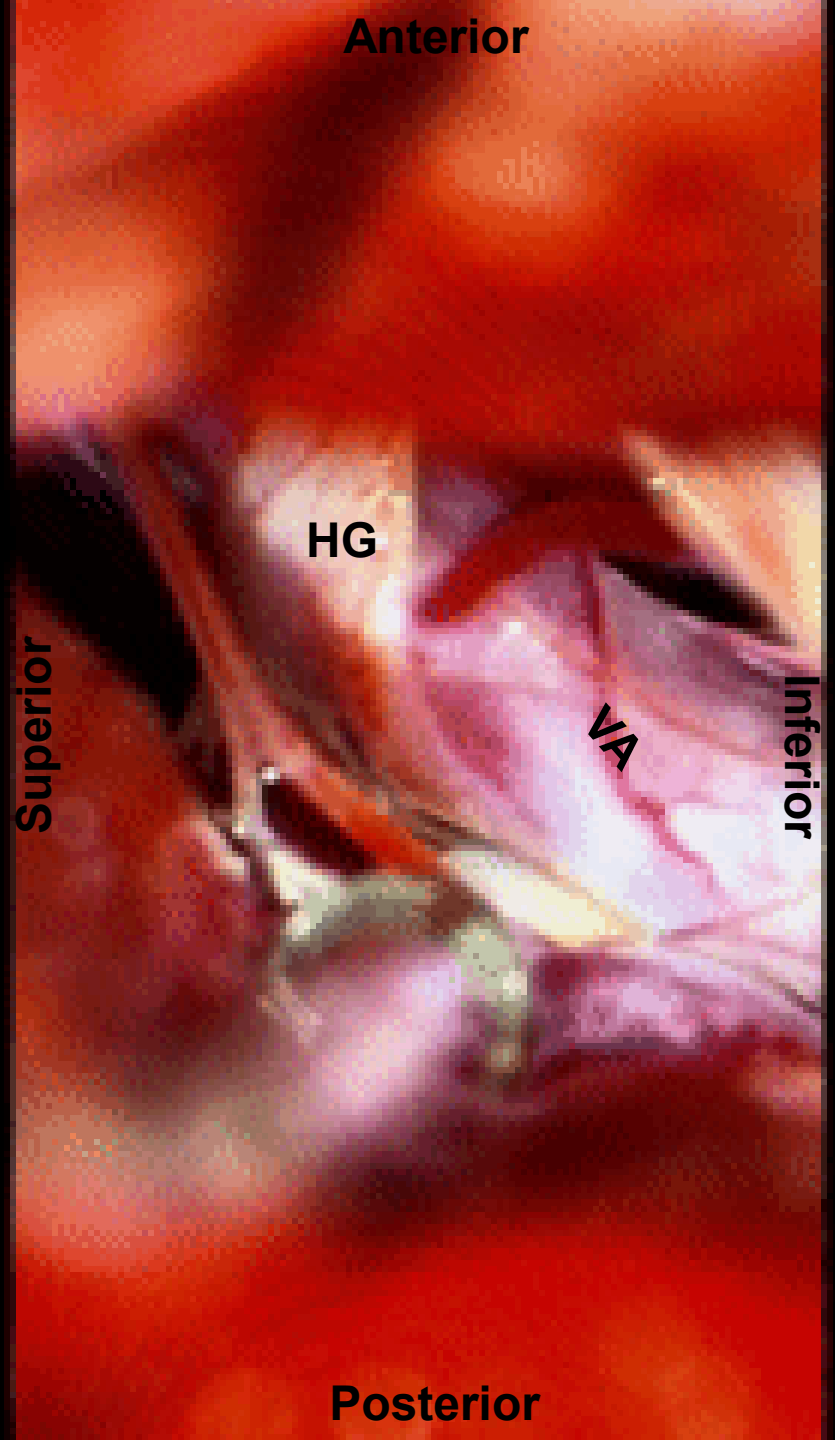

HG = CN XII

Video courtesy of
Dr. Jonathan Parish

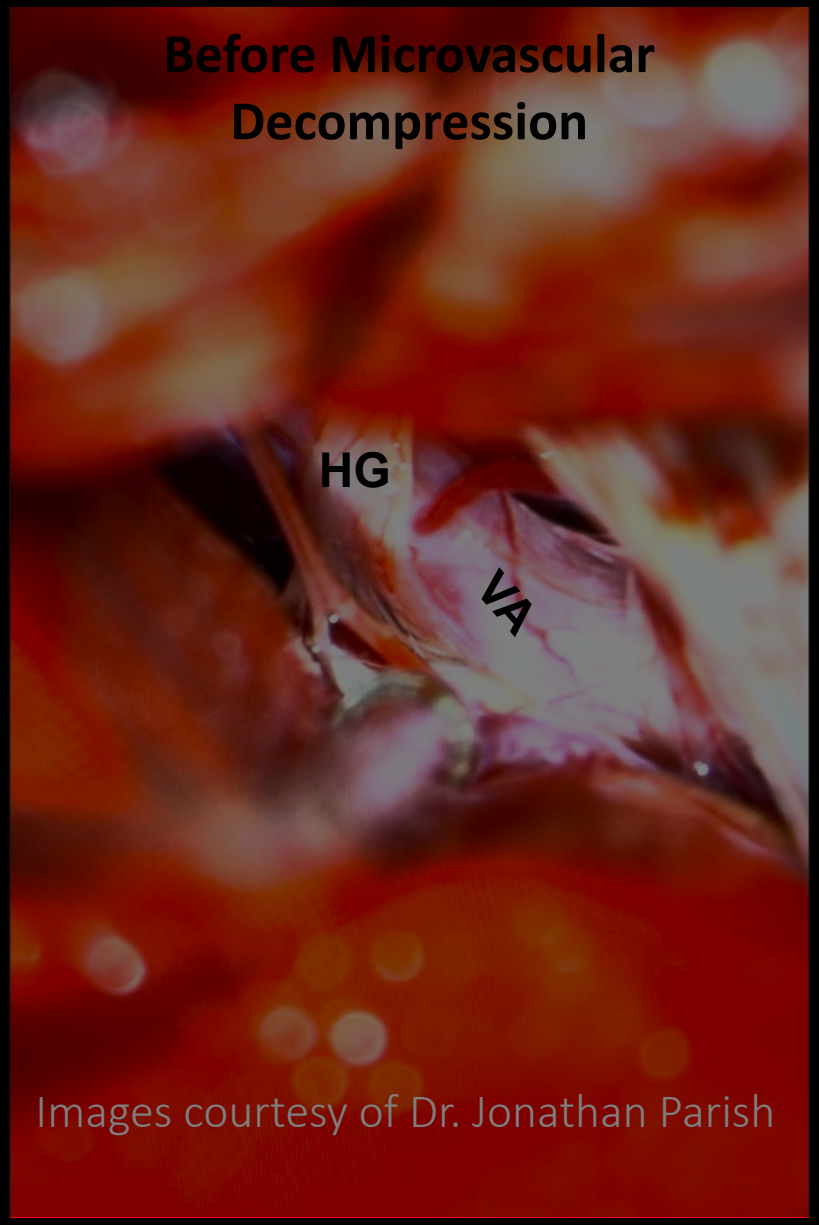

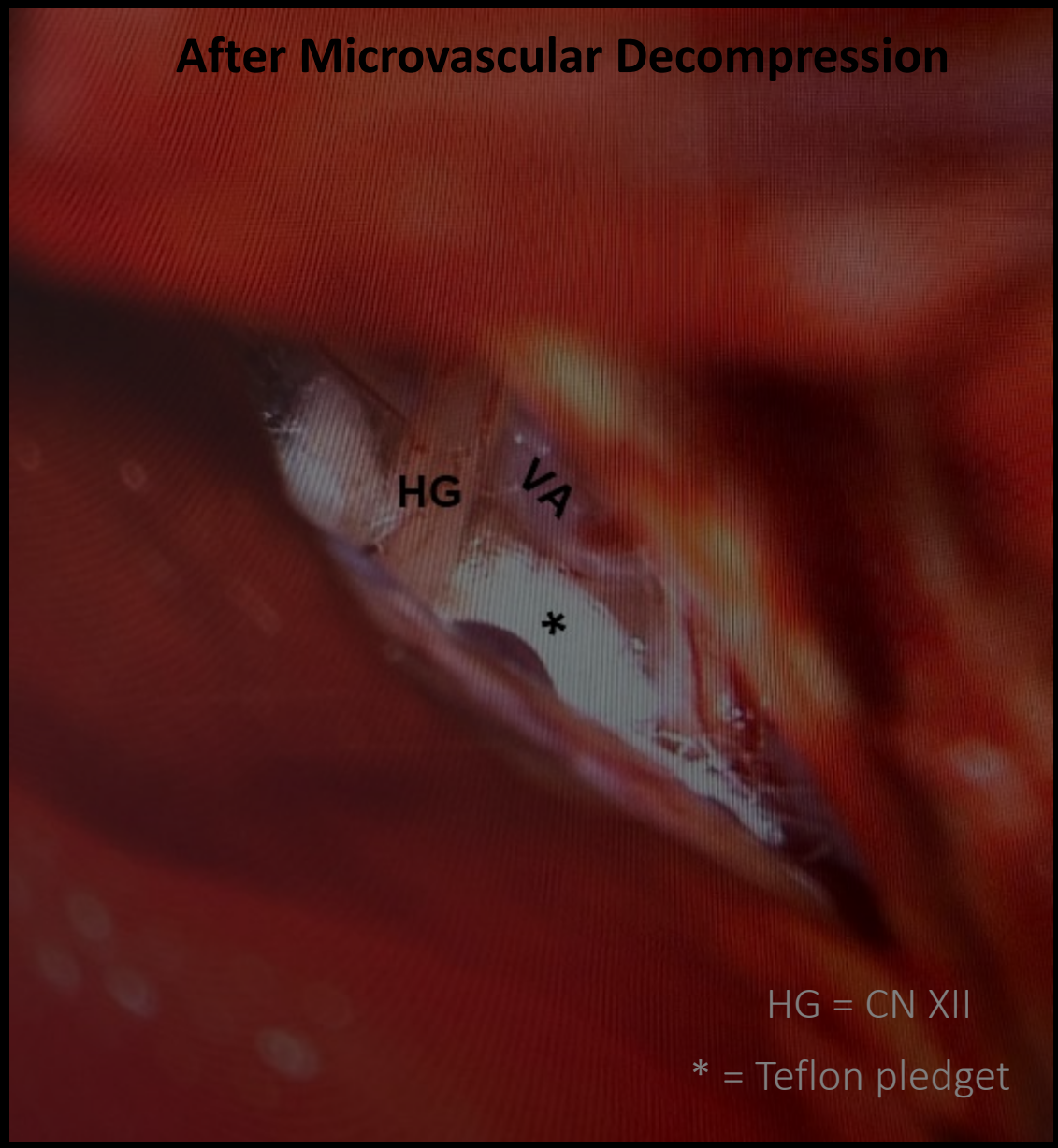

At **3-month follow-up**, speech, tongue mobility, and muscle bulk had **improved**.


Take Home
Points

Take Home Points

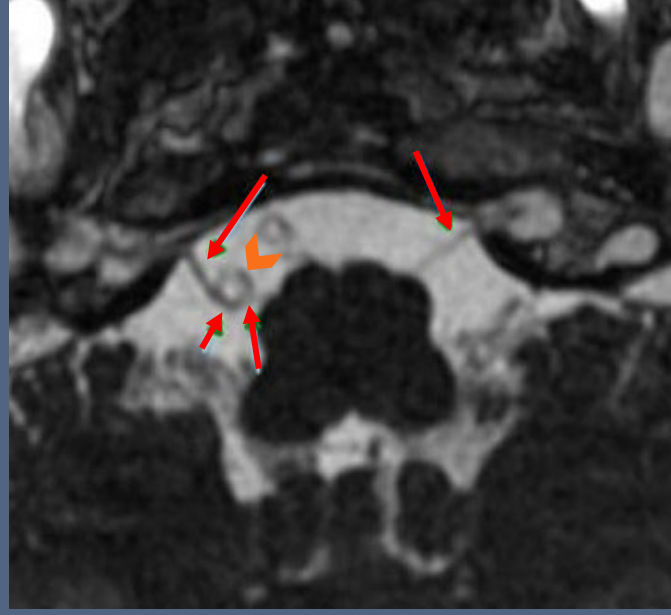

- Isolated CN XII neurovascular compression is **rare**
- **Vascular contact alone** on imaging is **insufficient** to diagnose symptomatic compression
- **Interpret imaging alongside the neurologic examination**—displacement, distortion, and thickening of HGN may strengthen suspicion of HGN palsy
- Concordant clinical, MRI, and intraoperative findings may identify selected patients who could benefit from **microvascular decompression**.

Literature Review

No.	Author (year)	Age, sex	Site	Compressing vessel	Treatment	Outcome
1	Morini et al. (1998)	77, M	Left	Vertebral artery	None	Unchanged
2	Graham et al. (2007)	77, M	Right	Basilar artery	None	Unchanged
3	Cheong et al. (2011)	32, M	Left	Vertebral artery	Microvascular decompression	Improved tongue movement at 3-month follow-up
4	Kollmann et al. (2017)	65, F	Right	Vertebral artery	None	Unchanged
5	Ekuma et al. (2017)	72, M	Left	Posterior inferior cerebellar artery	Microvascular decompression	Progressive improvement in tongue movement & swallowing at 1-year follow-up
6	Hikichi et al. (2020)	51, F	Right	Persistent primitive hypoglossal artery	Anti-hypertensive therapy	Complete resolution of symptoms after 12 months
7	Barkyoumb (2025)	62, F	Right	Posterior inferior cerebellar artery	Microvascular decompression	Complete resolution of symptoms at 3-month follow up

References

- Bademci G, Batay F, Yaşargil MG. “Triple cross” of the hypoglossal nerve and its microsurgical impact to entrapment disorders. Minimally invasive neurosurgery : MIN. 2006 Aug;49(4):234–7. https://pubmed.ncbi.nlm.nih.gov/17041836/
- Barkyoumb D, York AA, Zhao X, Dunn IF, Graffeo CS. Hemilingual spasm treated with microvascular decompression of the posterior inferior cerebellar artery: Illustrative case. Journal of neurosurgery Case lessons. 2025; 9(12):CASE24869. https://pubmed.ncbi.nlm.nih.gov/40127472/
- Cheong JH, Kim JM, Yang MS, Kim CH. Resolution of isolated unilateral hypoglossal nerve palsy following microvascular decompression of the intracranial vertebral artery. Journal of Korean Neurosurgical Society. 2011 Mar;49(3):167–70. https://pubmed.ncbi.nlm.nih.gov/21556237/
- Goto T, et al. Unilateral isolated hypoglossal nerve palsy due to pathologically adherent PICA fusiform aneurysm – a case report. Surgical Neurology International. 2017;8(1):114. https://surgicalneurologyint.com/surgicalint-articles/unilateral-isolated-hypoglossal-nerve-palsy-due-to-pathologically-adherent-pica-fusiform-aneurysm-a-case-report/
- Graham RM, Thomson EF, Baldwin AJ. Isolated hypoglossal nerve palsy due to a vascular anomaly. International Journal of Oral and Maxillofacial Surgery . 2007 Aug; 36(8):759–61. https://www.ijoms.com/article/S0901-5027(07)00099-9/abstract
- Guclu B, et al. Cranial nerve vascular compression syndromes of the trigeminal, facial and vago-glossopharyngeal nerves: Comparative anatomical study of the central myelin portion and transitional zone; correlations with incidences of corresponding hyperactive dysfunctional syndromes. Acta neurochirurgica. 2011 Dec; 153(12):2365–75. https://pubmed.ncbi.nlm.nih.gov/21947457/
- Hikichi H, et al. Hypoglossal nerve palsy due to compression by a persistent primitive hypoglossal artery: Case report. Journal of Stroke and Cerebrovascular Diseases. 2020 Feb; 29(2):104459. https://www.strokejournal.org/article/S1052-3057(19)30542-7/abstract
- JANNETTA PJ. Neurovascular compression in cranial nerve and systemic disease. Annals of Surgery. 1980 Oct;192(4):518–25.
- Keane JR. Twelfth-nerve palsy. Archives of Neurology. 1996 June 1;53(6):561.
- Kollmann P, Raucq E, Fransen P. Isolated hypoglossal nerve paralysis and hypoglossal-vertebral entrapment syndrome. Acta neurologica Belgica. 2017 Mar; 117(1):377–80. https://pubmed.ncbi.nlm.nih.gov/27255918/
- Morini A, et al. Isolated hypoglossal nerve palsy due to an anomalous vertebral artery course: Report of two cases. Italian journal of neurological sciences. 1998 Dec; 19(6):379–82. https://pubmed.ncbi.nlm.nih.gov/10935834/
- Węgiel A, et al. Hypoglossal nerve neuropathies—Analysis of causes and anatomical background. Biomedicines. 2024 Apr 14; 12(4):864. https://www.ncbi.nlm.nih.gov/pmc/articles/PMC11048189/
- Yousry I, et al. Detailed anatomy of the intracranial segment of the hypoglossal nerve: Neurovascular relationships and landmarks on magnetic resonance imaging sequences. Journal of neurosurgery. 2002 June; 96(6):1113–22. https://pubmed.ncbi.nlm.nih.gov/12066914/