Toxic or Post-Hypoxic?

Progressive Leukoencephalopathy Following Heroin Overdose

A case of overlapping toxic and hypoxic injury

50th Annual Southeastern Neuroradiological Society Meeting

Melissa Lou Silva, MD · State University of Ceará, Brazil
Cameron Henry, MD · Vanderbilt University Medical Center

Clinical timeline

45-YEAR-OLD MAN

Cocaine and heroin overdose

Respiratory failure
Intubation

INITIAL HOSPITALIZATION

Initial MRI: confluent bilateral white matter abnormalities

FIVE DAYS AFTER DISCHARGE

Progressive confusion, agitation, and erratic behavior

READMISSION

Neurologic decline prompted repeat MRI

Initial MRI: white matter injury

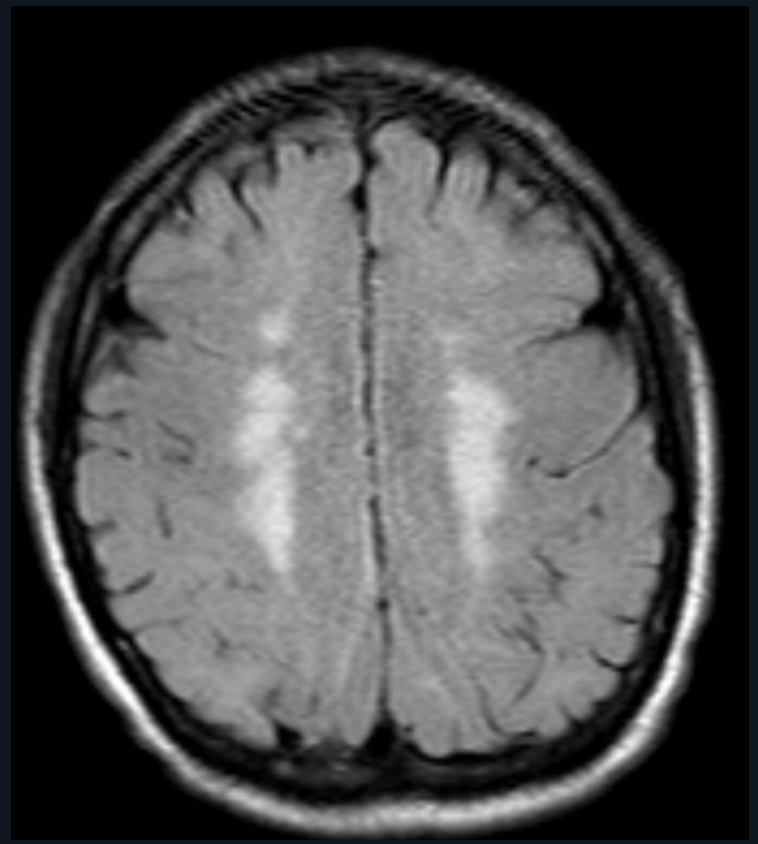

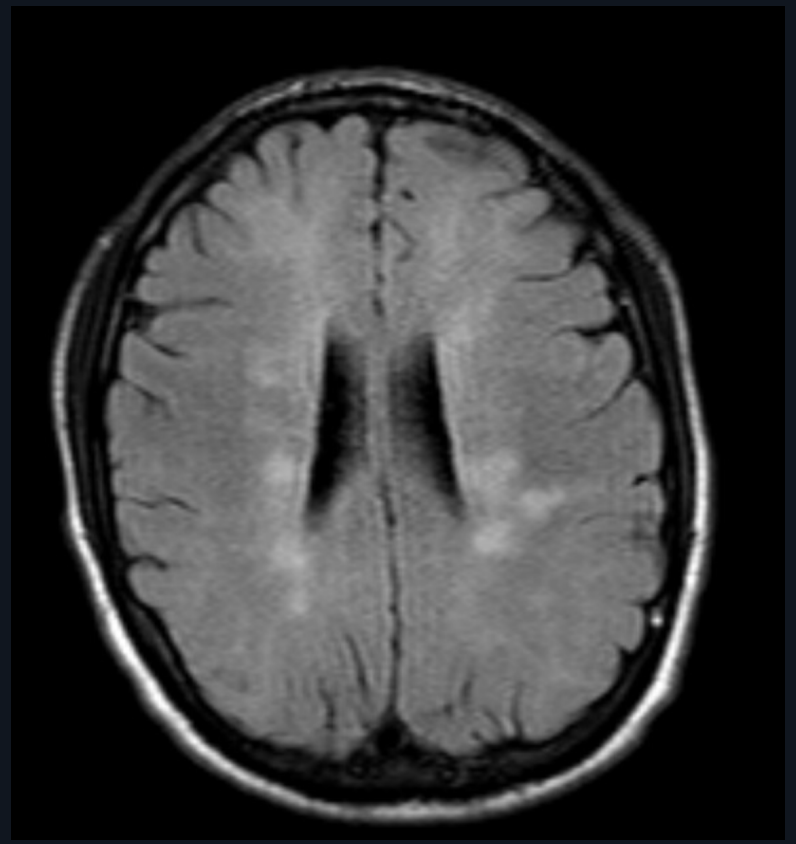

Reported: confluent bilateral cerebral white matter signal abnormalities.

Serial MRI: 1 Month progression

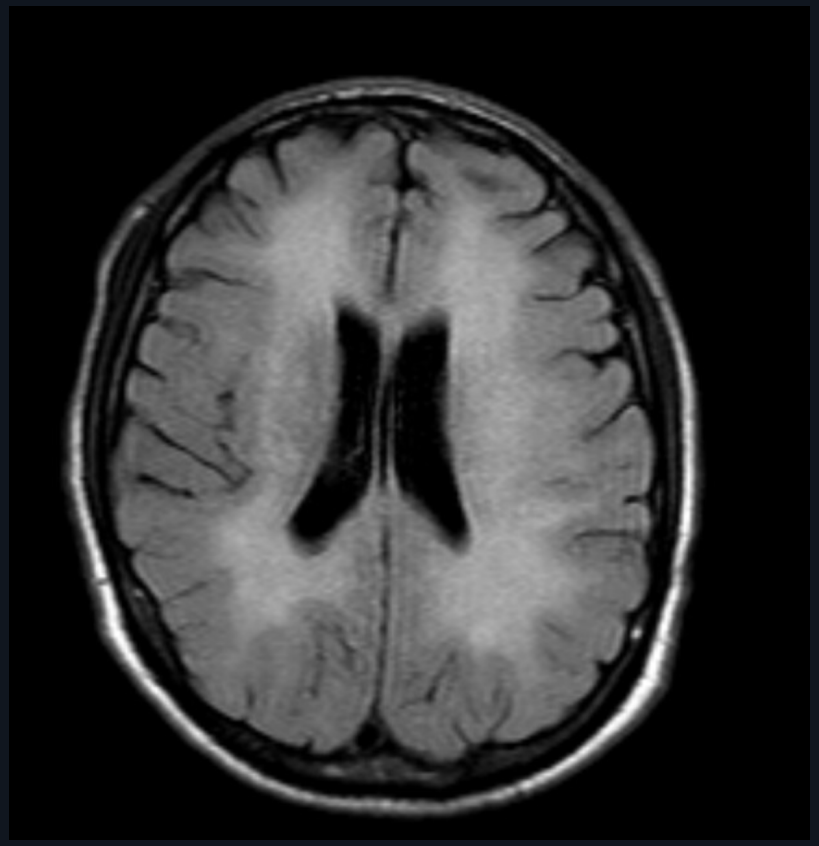

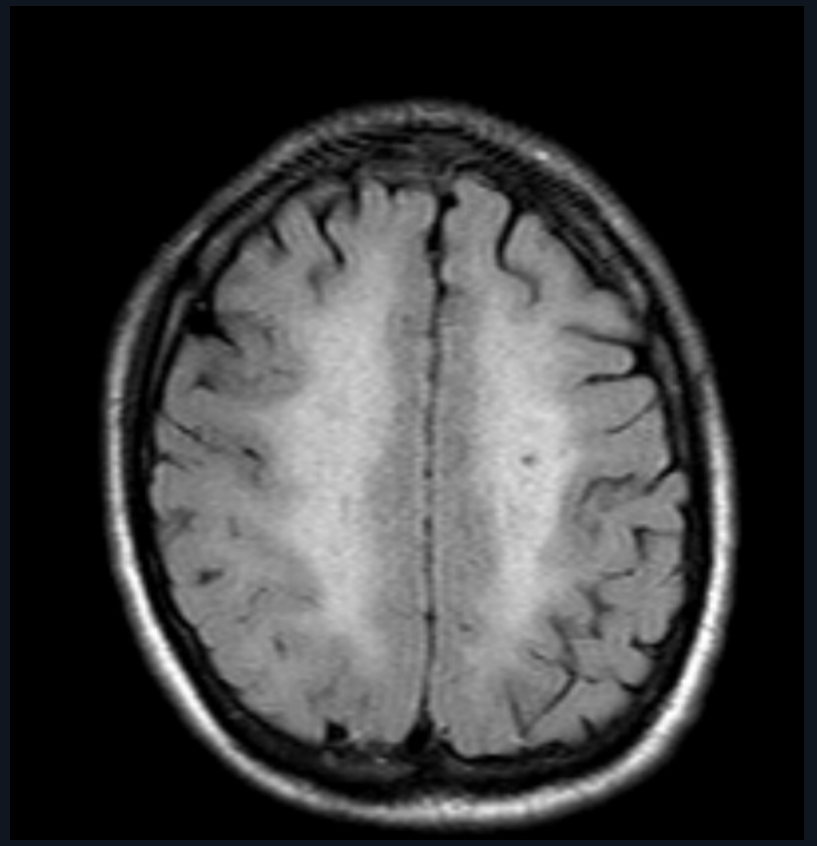

Reported: marked progression, predominantly in frontal and parietal white matter.

Deep gray matter: globus pallidus

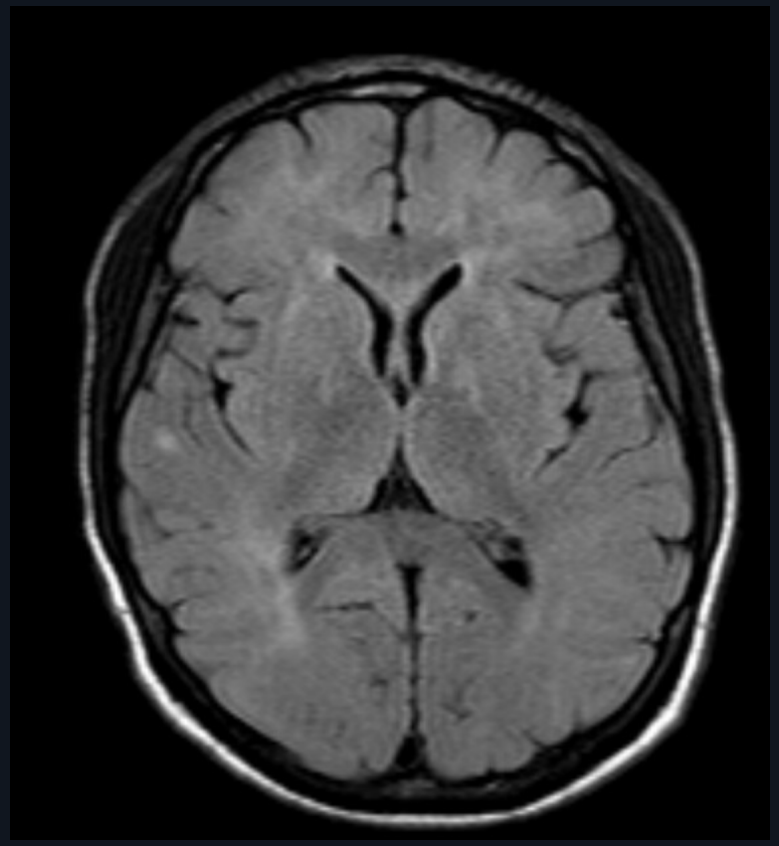

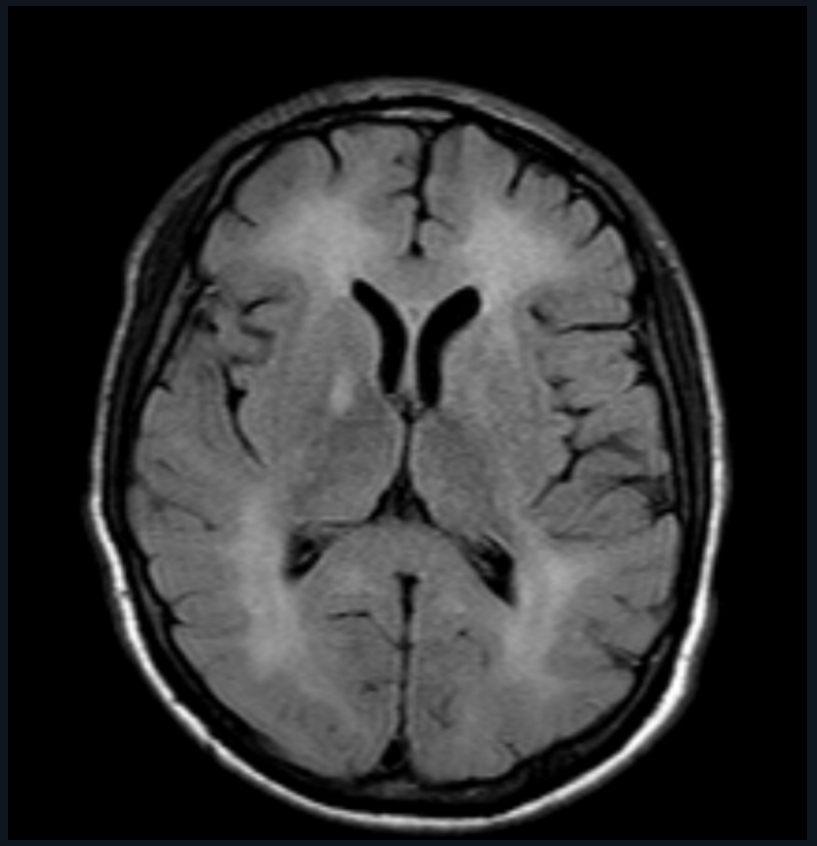

Reported new pallidal involvement complicates a diagnosis of isolated delayed white matter injury.

Posterior fossa sparing

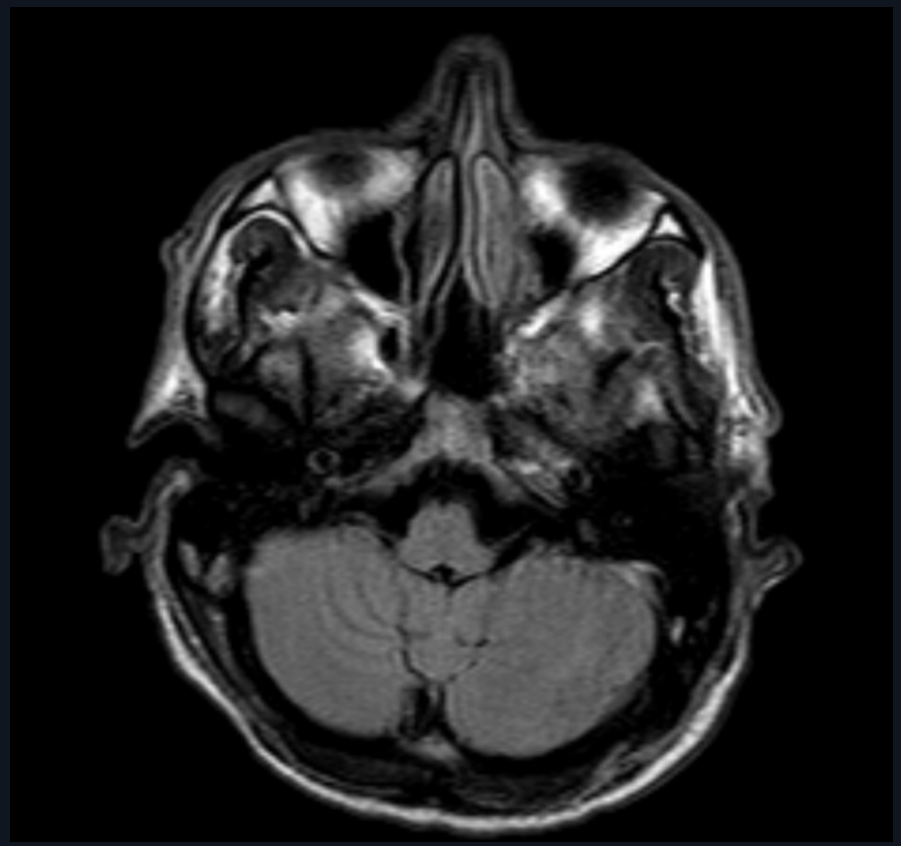

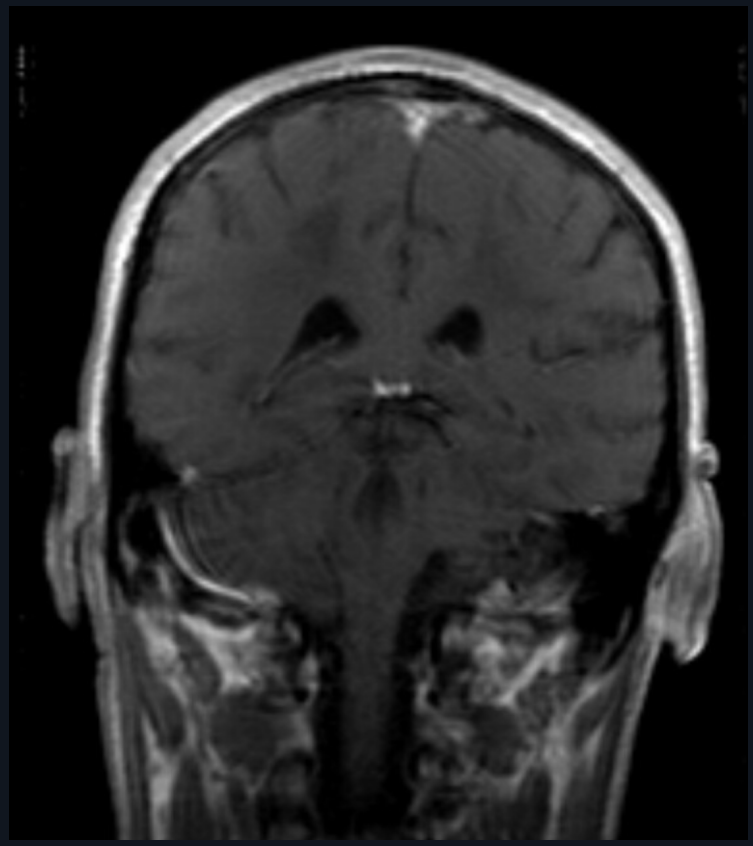

Reported cerebellar and brainstem sparing helps refine the pattern, but is not diagnostic alone.

Diffusion: DWI and ADC correlation

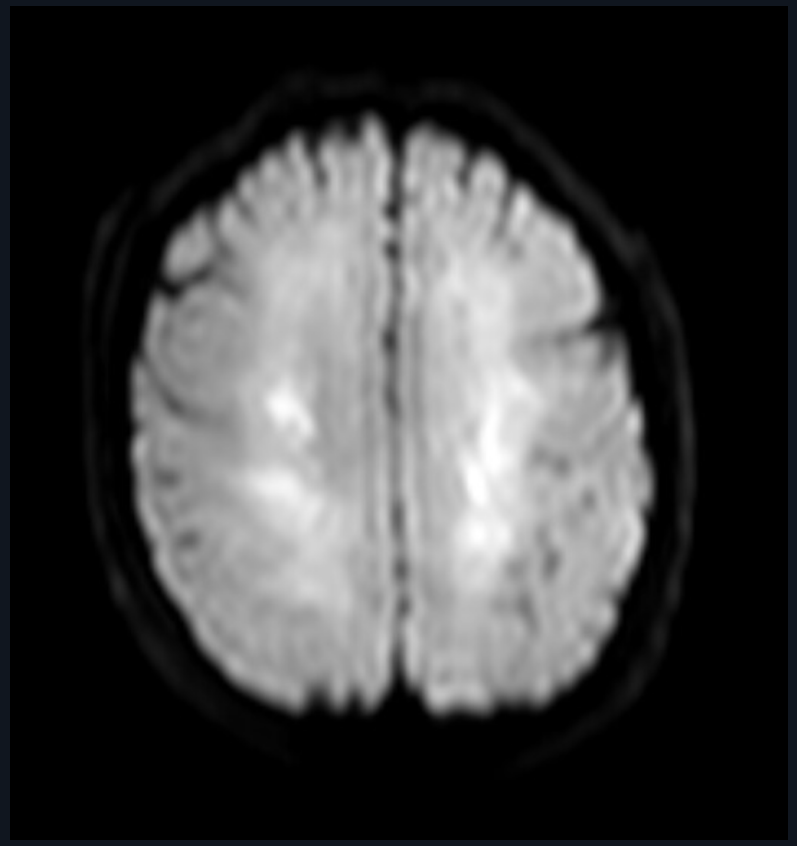

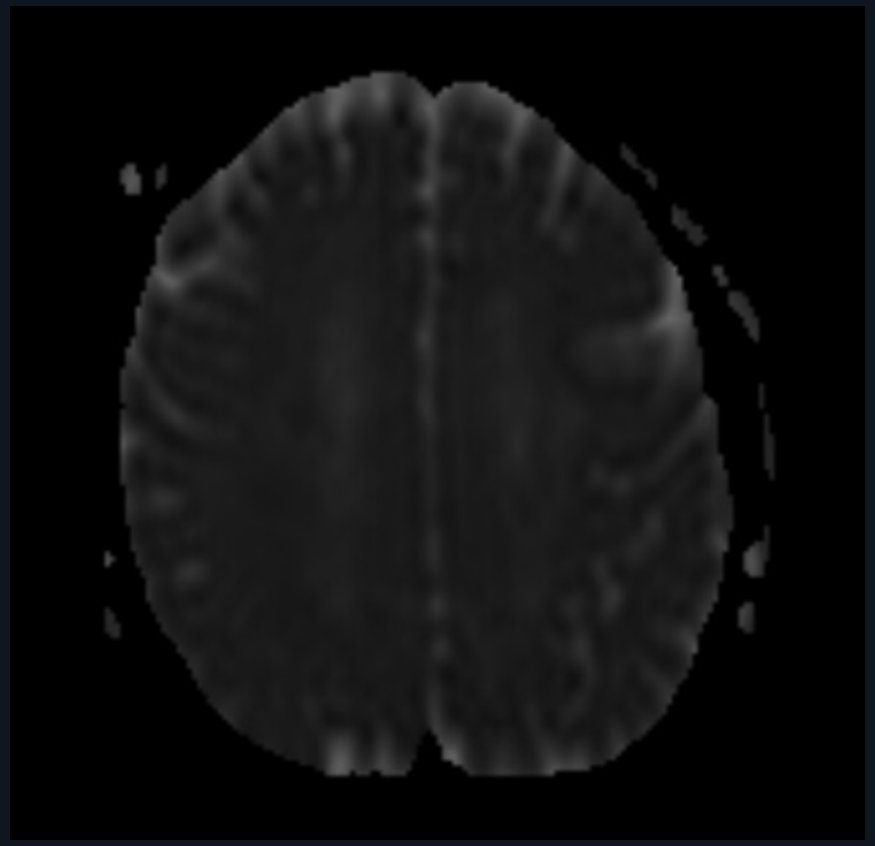

Restricted diffusion indicates tissue injury. It does not, by itself, establish acute infarction.

Toxic versus delayed post-hypoxic injury

Feature	Delayed post-hypoxic pattern	Toxic pattern
Clinical course	Relapse after recovery from hypoxia	Exposure-associated injury
White matter	Confluent supratentorial disease	Distribution varies by agent / route
Posterior fossa	Often spared	Often involved in classic inhalational heroin injury
Diffusion	Restriction may be extensive	Restriction may also occur

These processes can overlap after overdose. Timing and distribution should guide interpretation.

Working interpretation and remaining questions

FEATURES SUPPORTING A HYPOXIC COMPONENT

Respiratory failure requiring intubation

Delayed clinical worsening

Progressive supratentorial white matter disease

INFORMATION TO VERIFY

True recovery / lucid interval

Overdose-to-relapse interval and scan dates

Heroin route and pallidal lesion timing

Progressive toxic / hypoxic leukoencephalopathy. A delayed post-hypoxic component is plausible.

Management

SUPPORTIVE CARE

Neurologic monitoring

Rehabilitation as clinically appropriate

Aspiration prevention and management of complications

THERAPEUTIC LIMITATIONS

No established disease-modifying therapy

Coenzyme Q10 listed in the original plan

Benefit in this setting remains unproven

Treatment and goals of care should reflect neurologic function and the overall clinical course.

Reported outcome

NEUROLOGIC COURSE

Persistent severe impairment

No reported neurologic improvement

SUBSEQUENT CARE

Readmission with aspiration pneumonia and hypoxemia

Transition to comfort-focused care

Nursing facility discharge with hospice

Reported outcome: severe persistent disability with hospice care.

Take-home points

1 **The clinical timeline matters**

Confirm recovery and relapse timing before labeling classic delayed post-hypoxic injury.

2 **Serial imaging and distribution matter**

Compare matched FLAIR views, deep gray matter, posterior fossa, and DWI/ADC.

3 **Mechanisms may overlap**

Toxic and hypoxic injury can coexist. Restricted diffusion alone does not establish infarction.

References:

I. Kontos N, Parsons MW, Biffi A, González RG. **Case 19-2021: A 54-Year-Old Man with Irritability, Confusion, and Odd Behaviors.** *N Engl J Med.* 2021;384(25):2446–2455. doi:10.1056/NEJMcpc2027093

II. Cheng MY, Chin SC, Chang YC, et al. **Different routes of heroin intake cause various heroin-induced leukoencephalopathies.** *J Neurol.* 2019;266(2):316–329. doi:10.1007/s00415-018-9131-1

III. Chen-Plotkin AS, Pau KT, Schmahmann JD. **Delayed Leukoencephalopathy After Hypoxic-Ischemic Injury.** *Arch Neurol.* 2008;65(1):144–145. doi:10.1001/archneurol.2007.4

IV. Özütemiz C, Roshan SK, Kroll NJ, et al. **Acute Toxic Leukoencephalopathy: Etiologies, Imaging Findings, and Outcomes in 101 Patients.** *AJNR Am J Neuroradiol.* 2019;40(2):267–275. doi:10.3174/ajnr.A5947

V. Alambyan V, Pace J, Miller B, et al. **The Emerging Role of Inhaled Heroin in the Opioid Epidemic: A Review.** *JAMA Neurol.* 2018;75(11):1423–1434. doi:10.1001/jamaneurol.2018.1693