GRANULAR CELL TUMOR

LEON WU, DO

HIBA FAZAL-UR-REHMAN,MS4

ANANDRAJ KANWAR, MD



CLINICAL PRESENTATION

- 25-year-old female with a history of recently diagnosed pituitary micro-adenoma, associated hypothyroidism and adrenal insufficiency, presented to the ED on 6/26/2026 with exertional shortness of breath, worsening angioedema, cervical lymphadenopathy, and dysphagia.
- Patient's history is also notable for SLE with lupus nephritis and possible myocarditis, for which she is undergoing evaluation and treatment by rheumatology, nephrology, and cardiology.

IMAGING



Neck soft tissue CT shows a 1.4 x 1.4 cm soft tissue mass in the posterior wall of the upper trachea (red arrows), resulting in tracheal narrowing

IMAGING



Neck soft tissue CT shows a 1.4 x 1.4 cm soft tissue mass in the posterior wall of the upper trachea (red arrows), resulting in tracheal narrowing

IMAGING

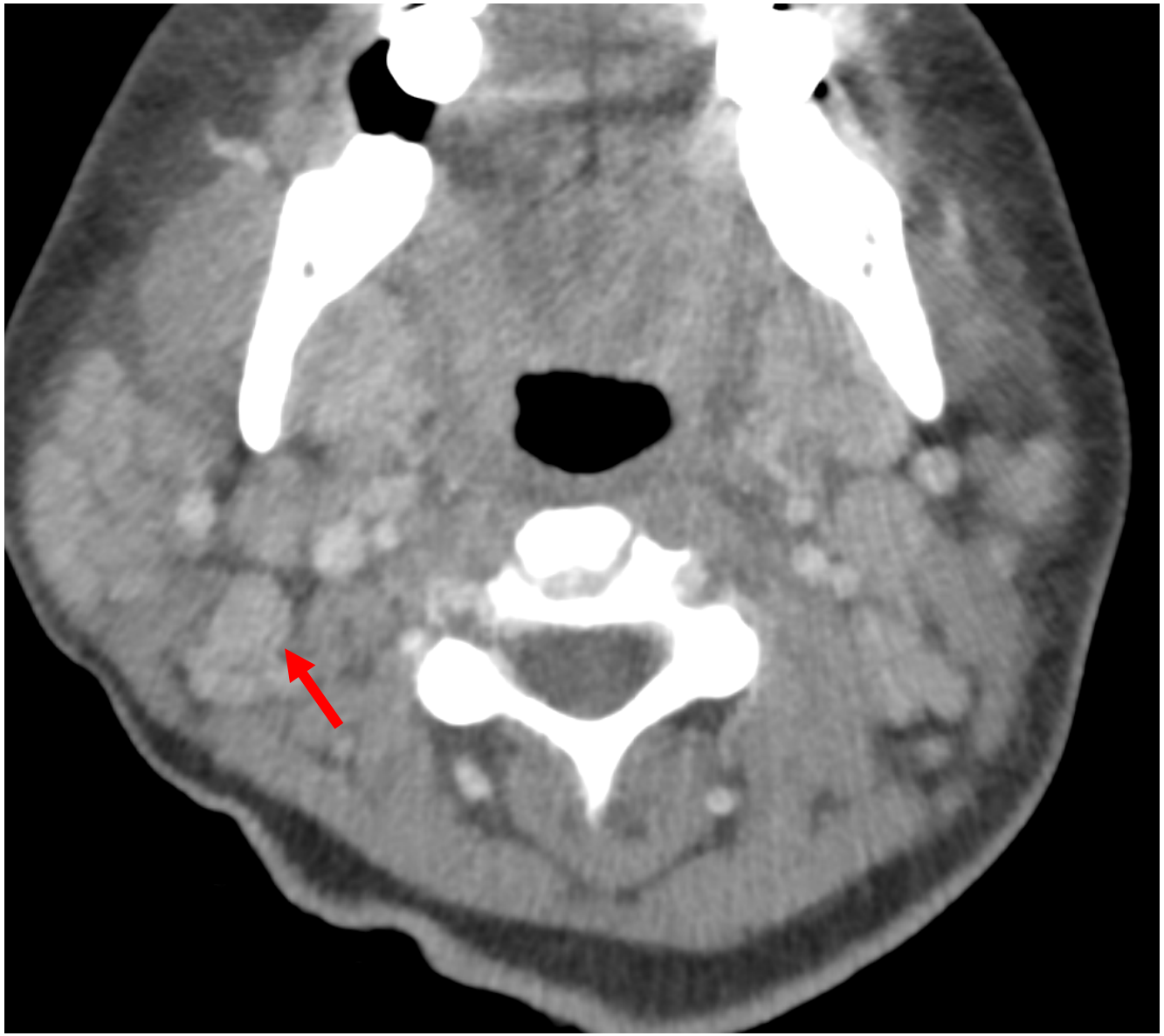

Bilateral cervical lymphadenopathy is noted, including a right level 2B node measuring 1.1 cm in short axis (red arrow)

IMAGING

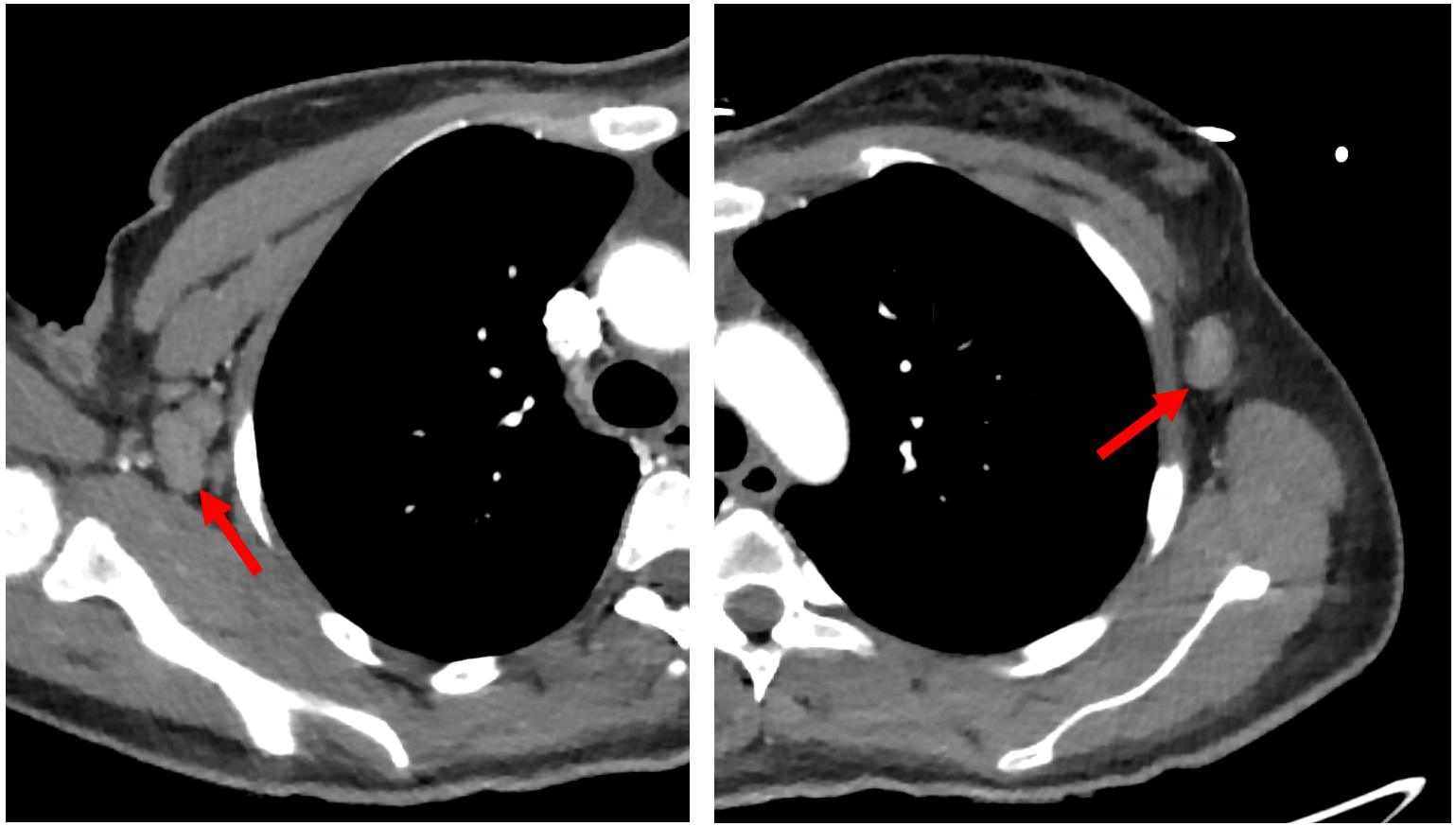

Bilateral axillary lymphadenopathy is also noted, including two enlarged nodes measuring 1.2cm in short axes (red arrows)

MANAGEMENT

- Laryngoscopy and bronchoscopy demonstrated a 1-2cm right posterolateral tracheal submucosal mass. Several biopsies were obtained, and pathology confirmed a granular cell tumor, with supportive immunohistochemical staining for SOX-10, S100, and CD68.
- A right cervical lymph node biopsy was performed on 7/17/2026; however, the specimen was non-diagnostic due to scant cellularity and limited number of lymphocytes.
- During this period, patient received continued dexamethasone therapy, which improved her facial swelling.

OUTCOME

- Patient's facial edema and dysphasia improved following an extended inpatient course.
- With respect to her granular cell tumor, repeat cross-sectional imaging of the neck is planned in 3-6 months for interval assessment.
- Repeat tissue sampling, particularly of her axillary lymph nodes, may be considered to evaluate for possible metastatic disease. If metastatic disease is confirmed, further staging with PET/CT or cross-sectional imaging of the abdomen and pelvis should be considered.

TAKE HOME POINTS

- Although rare, granular cell tumor (GCT) should be considered in the differential diagnosis of tracheal, bronchial, or laryngeal soft tissue masses.
- GCTs are typically benign and indolent, and malignant transformation and metastatic disease are rare.
- Our patient's cervical and axillary lymphadenopathy raises concern for metastatic involvement. However, metastatic GCT has not been pathologically confirmed in our case, highlighting the need for further evaluation when clinical suspicion remains high and the challenge of distinguishing between benign and malignant GCTs with extensive lymphadenopathy, especially with multiple concurrent medical comorbidities.
- Accurate diagnosis of GCT requires correlation of immunohistochemistry, clinical and image findings.

REFERENCES

- Rizzo A, Serban ED, Ricci AD, Nannini M, Saponara M, Cancellieri A, et al. Granular cell tumor of the trachea as a rare cause of dyspnea in a young woman. *Respir Med Case Rep.* 2019;28:100961. doi:10.1016/j.rmcr.2019.100961.
- Houcine Y, Mlika M, Moussa C, Rouis H, Brahem E, Ismail O, et al. Granular cell tumor of the lung and tracheobronchial tree: two case-presentation with a review of the literature. *Rare Tumors.* 2023;15:20363613231187822. doi:10.1177/20363613231187822.
- Burton DM, Heffner DK, Patow CA. Granular cell tumors of the trachea. *Laryngoscope.* 1992;102(7):807-813. doi:10.1288/00005537-199207000-00010.
- Guarnieri T, Cardinale L, Macchia G, Cortese G, Veltri A. Multiphasic multidetector computed tomography study of a rare tracheal tumor: granular cell tumor. *Case Rep Pulmonol.* 2014;2014:807430. doi:10.1155/2014/807430.