An Unexpected Cause of Cranial Neuritis

Lyme Neuroborreliosis

Multifocal cranial nerve enhancement

50th Annual Southeastern Neuroradiological Society Meeting

Kofi Boahene, BS · Meharry Medical College
Ronald Woodruff, MD · Vanderbilt University Medical Center
Cameron Henry, MD · Vanderbilt University Medical Center

Clinical presentation

26-YEAR-OLD WOMAN

10 days of headache

Dysphagia
Perioral numbness

NEUROLOGIC EXAM

Bilateral facial nerve palsies

Left arm and leg strength: 4/5

Remainder of examination reported as normal

Clinical timeline

1 **Symptom evolution**

Headache, then dysphagia and perioral numbness

2 **Neurologic evaluation**

Bilateral facial palsies and left-sided weakness

3 **Imaging and diagnostic workup**

Unremarkable CT, abnormal MRI, CSF and Lyme testing

4 **Treatment and response**

Doxycycline with rapid clinical improvement

Initial CT: no acute explanation



REPORTED FINDING

Initial CT was unremarkable

MRI followed to evaluate the cranial neuropathies

CT did not explain the clinical deficits. MRI supplied the key imaging clue.

MRI overview: multifocal cranial neuritis

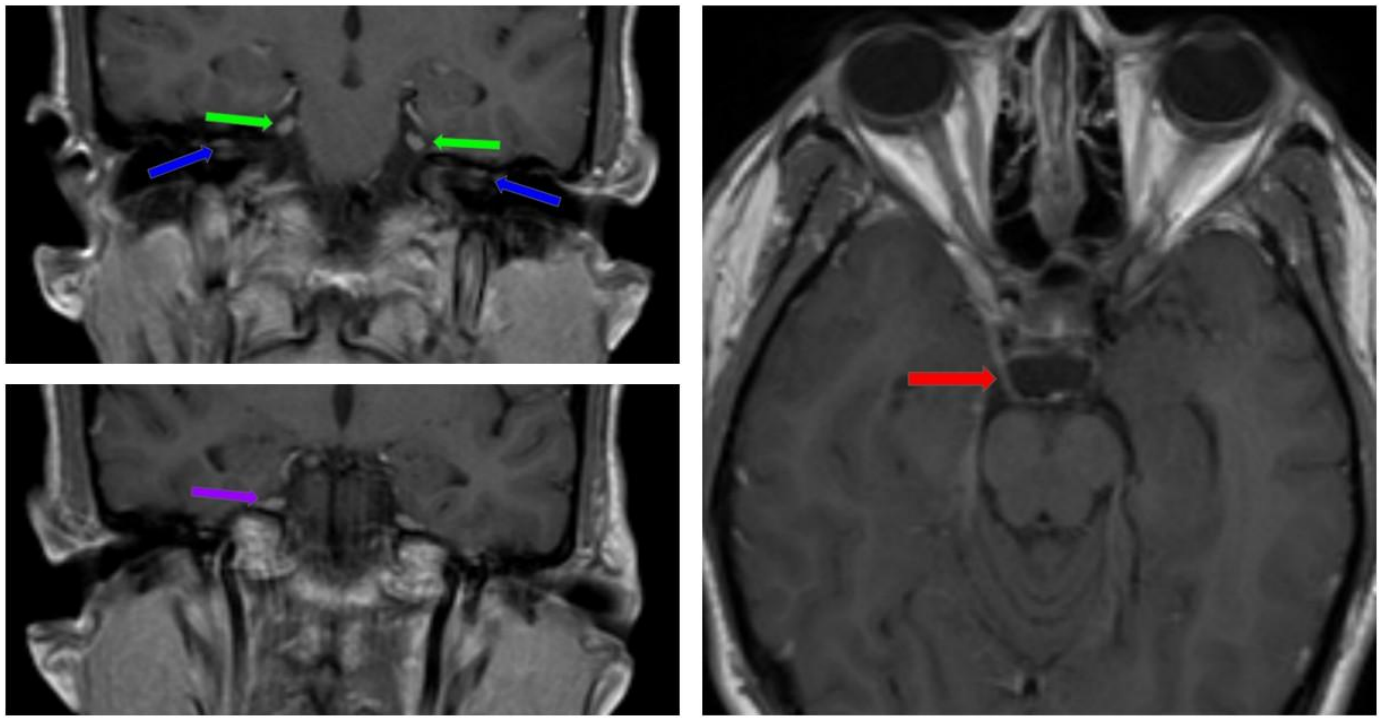

REPORTED NERVES

Bilateral CN V

Bilateral VII/VIII complexes

Right CN III

A multifocal pattern warrants investigation for a systemic infectious or inflammatory process.

CN V: bilateral trigeminal involvement

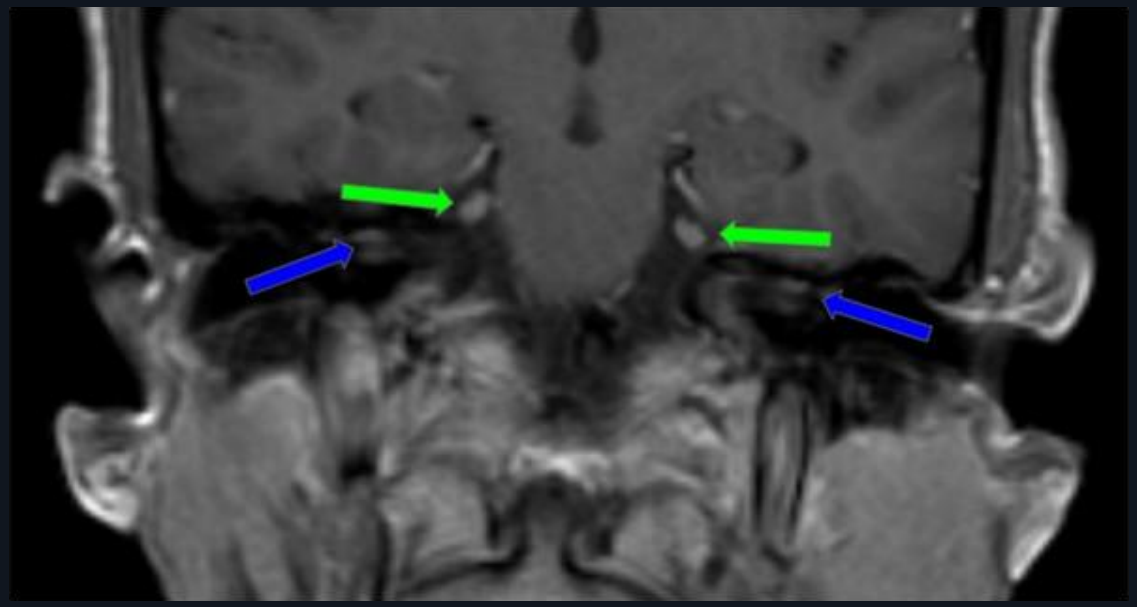

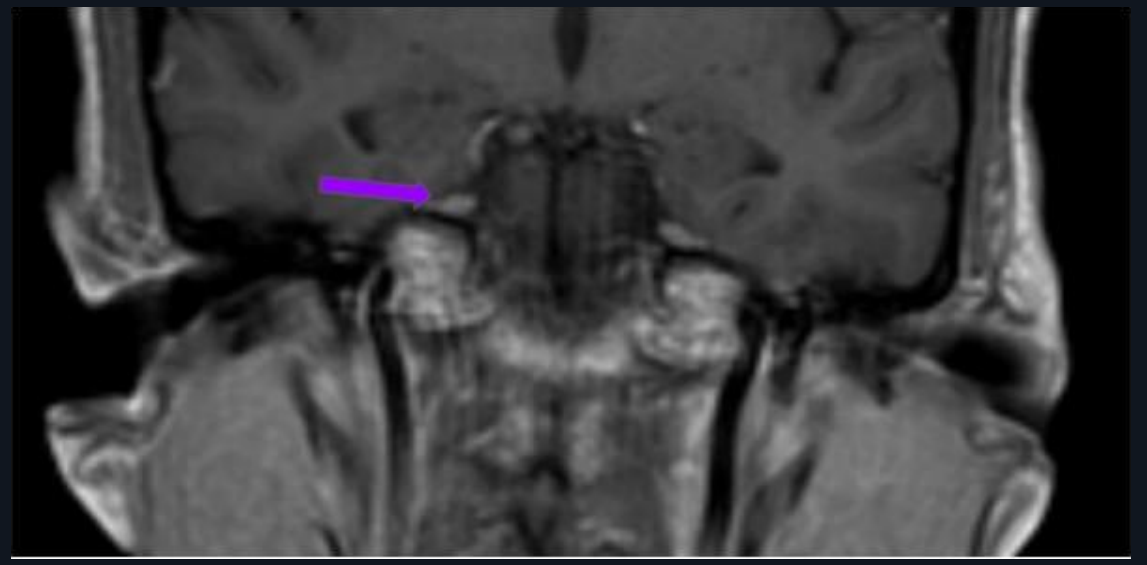

Coronal postcontrast T1: green arrows mark bilateral CN V, purple marks additional right CN V.

CN VII/VIII: internal auditory canal complexes

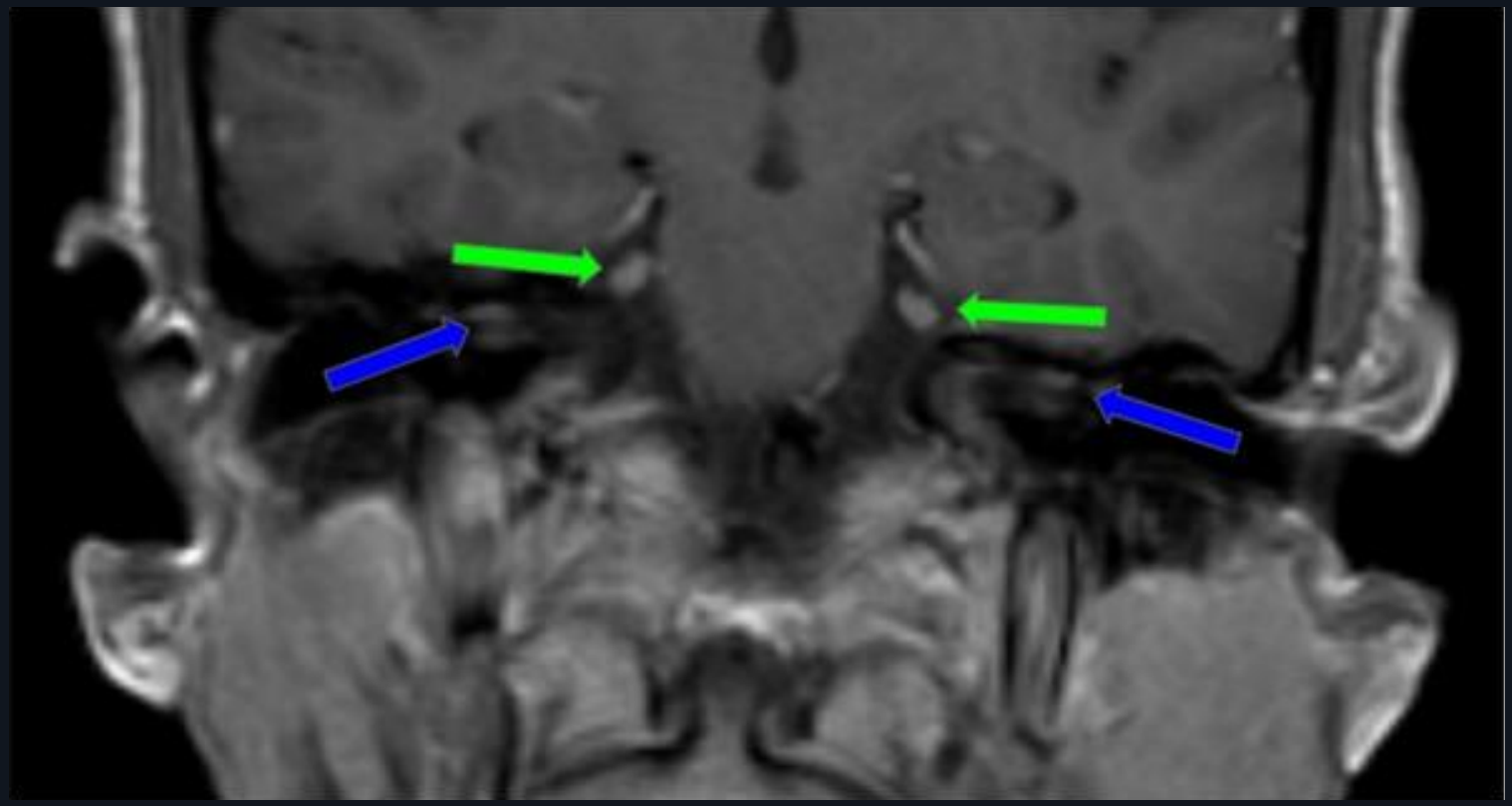

BLUE ARROWS

IAC-region enhancement

Bilateral facial palsies provide clinical correlation

VII/VIII involvement described in the case

Original blue arrows identify CN VII. The narrative describes involvement of the VII/VIII complexes.

CN III: right oculomotor involvement

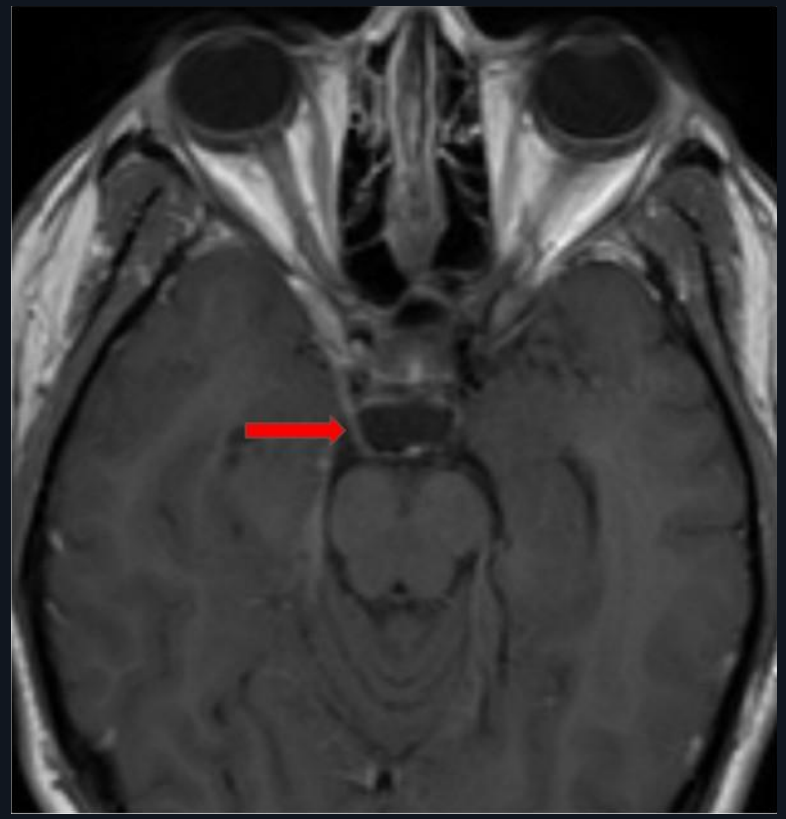

RED ARROW

Reported right CN III enhancement

Additional nerve involvement broadens the process beyond isolated facial neuritis

Axial postcontrast T1: original red arrow marks the reported right oculomotor nerve abnormality.

What is your differential?

Category	Examples to consider
Infectious	Lyme, viral neuritis, tuberculosis, syphilis
Inflammatory / granulomatous	Neurosarcoidosis, GBS spectrum
Neoplastic	Leptomeningeal malignancy, lymphoma

Bilateral facial palsy with additional cranial nerve enhancement should prompt a systemic workup.

CSF and serology: Lyme neuroborreliosis

CSF

Lymphocytic pleocytosis

Elevated protein

LYME TESTING

Positive B. burgdorferi IgM and IgG immunoblots

Diagnosis integrated the presentation, CSF, serology, and MRI

No recognized tick exposure was reported. Imaging supported the clinical diagnosis.

Treatment and reported outcome

TREATMENT

14-day course of doxycycline

Discharge to complete antibiotics

RESPONSE

Rapid clinical improvement

Continued resolution of neurologic symptoms

Clinical recovery was reported. Follow-up MRI was not supplied.

Take-home points

1. **Bilateral facial palsy deserves a broader workup**
   Additional cranial neuropathies suggest a systemic process.

2. **MRI provides a pattern, not a final diagnosis**
   Multifocal nerve enhancement requires clinical, CSF, and serologic correlation.

3. **Lyme is a treatable consideration**
   A recognized tick bite may be absent. Prompt diagnosis can guide effective treatment.

References

1. Lindland ES, et al. Imaging in Lyme neuroborreliosis. Insights Imaging. 2018 Oct;9(5):833-844. doi: 10.1007/s13244-018-0646-x. Epub 2018 Sep 4. PMID: 30187265; PMCID: PMC6206375.
2. Lantos PM, et al. Clinical Practice Guidelines by the Infectious Diseases Society of America (IDSA), American Academy of Neurology (AAN), and American College of Rheumatology (ACR): 2020 Guidelines for the Prevention, Diagnosis and Treatment of Lyme Disease. Clin Infect Dis. 2021 Jan 23;72(1):1-8. doi: 10.1093/cid/ciab049. PMID: 33483734.