Intraparenchymal Schwannoma: A Rare Benign Neoplasm and Frequent Mimic

Jineet Patel, M.D.; Thomas J Eluvathingal, M.D.

University of Virginia Health System
Department of Radiology and Medical Imaging

Clinical Presentation

- Several weeks of persistent light-headedness/dizziness with episodic vomiting
- Initially evaluated in the emergency department and diagnosed with vertigo
- Persistent symptoms prompted MRI brain with and without contrast
- Neurologic examinations were otherwise unremarkable apart from chronic hearing loss

Imaging – T2 axial

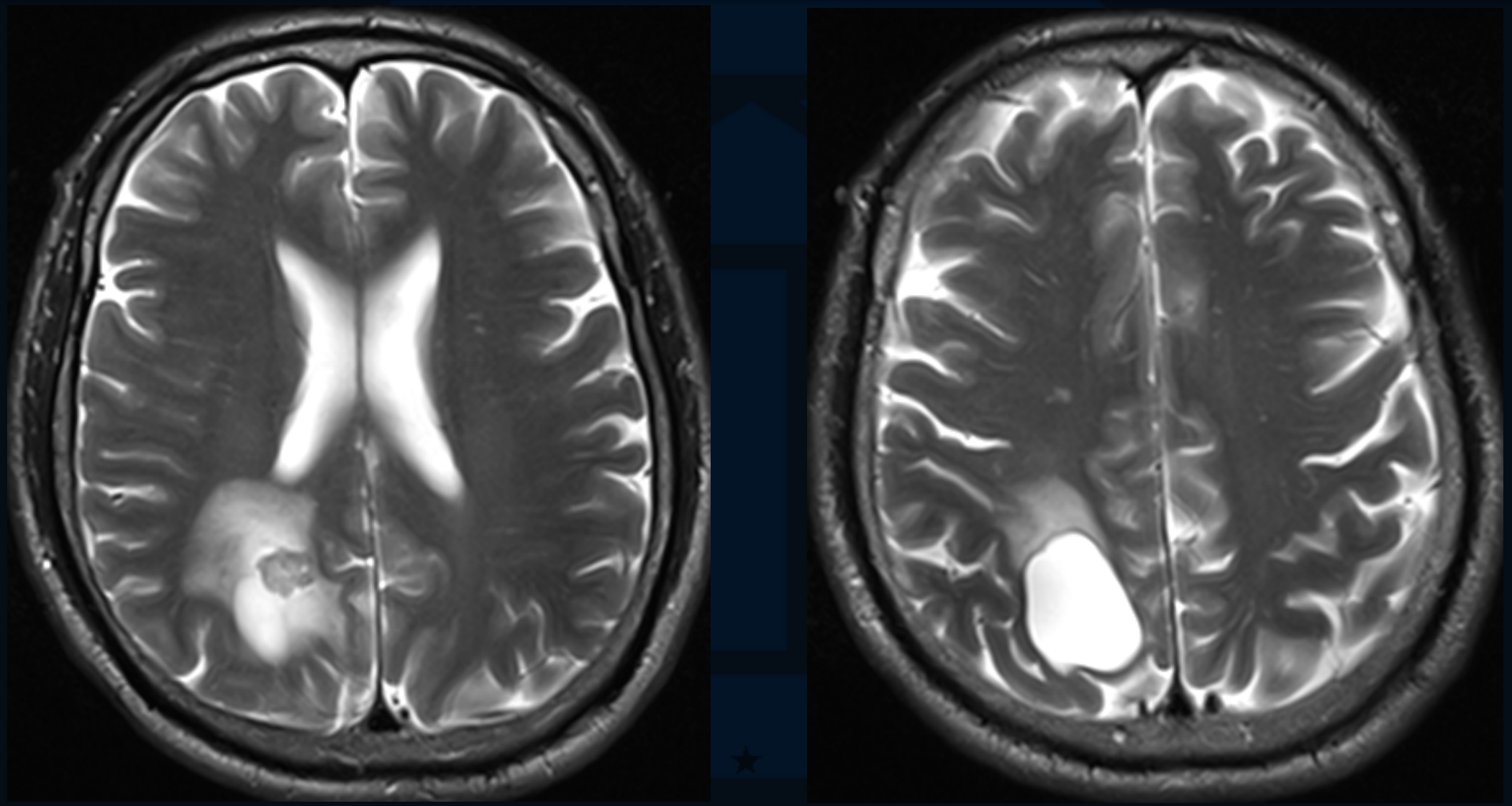

Imaging – FLAIR axial

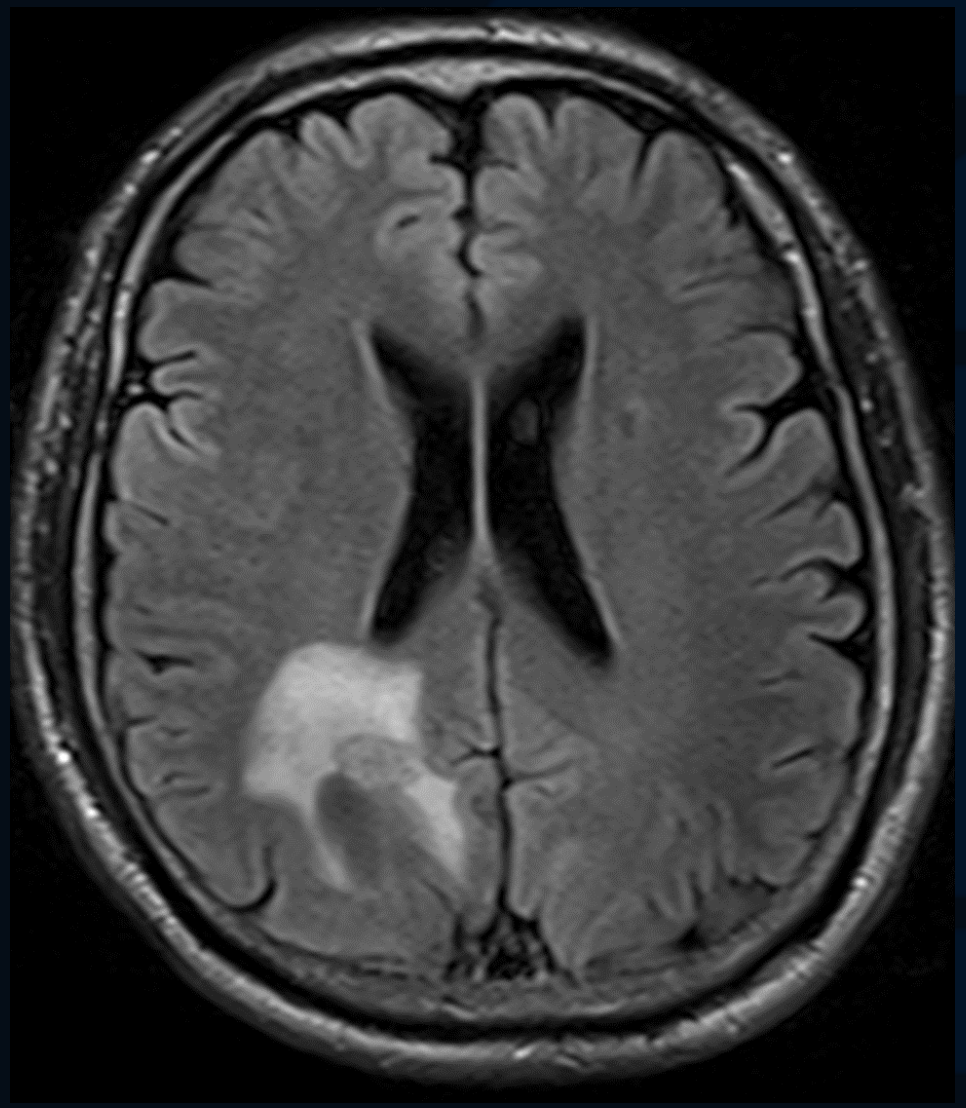

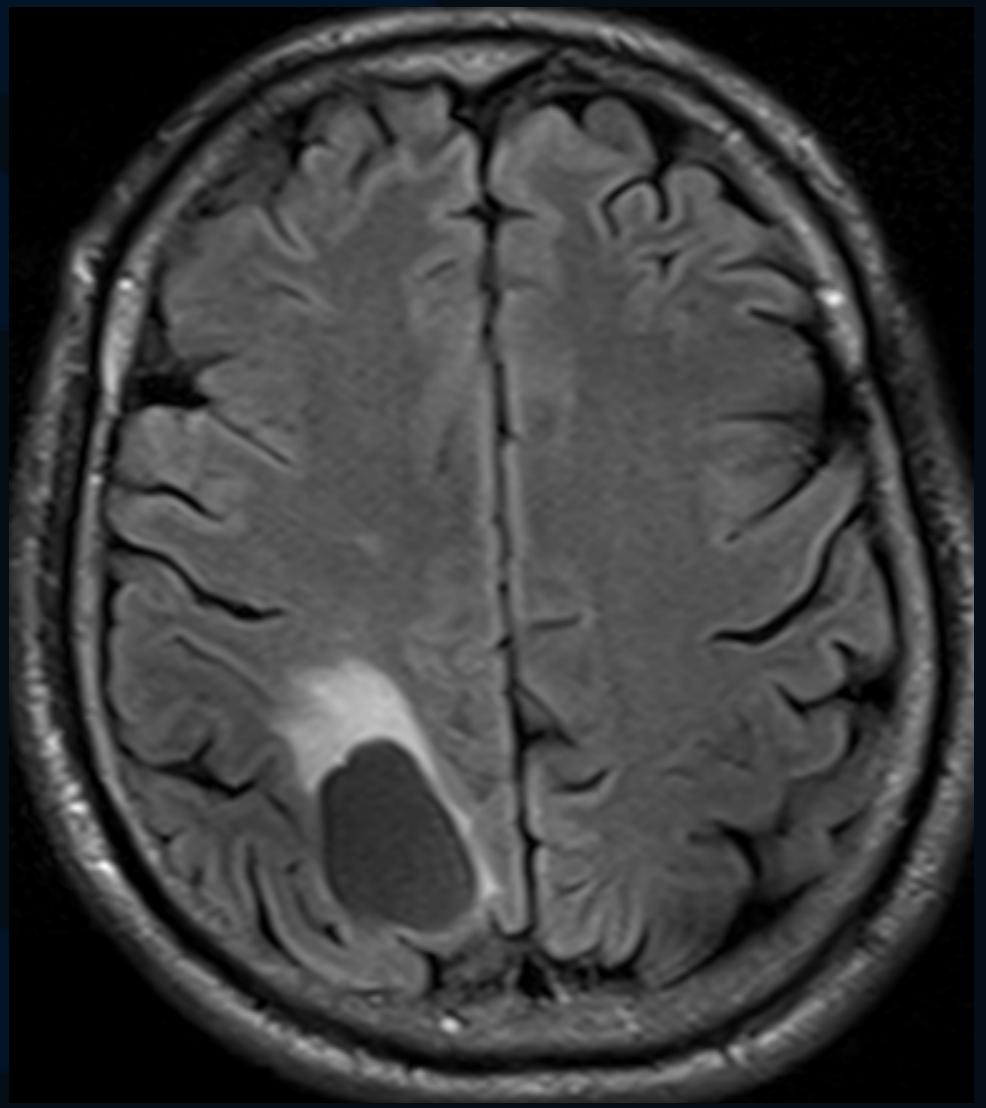

Imaging – T1 pre and post-contrast

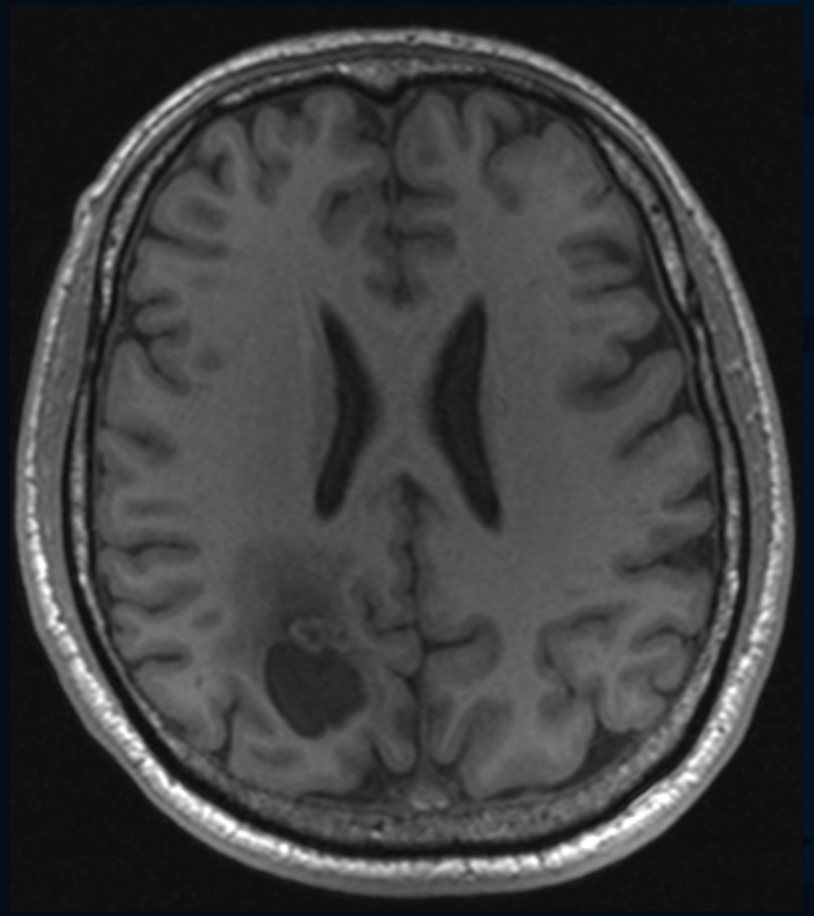

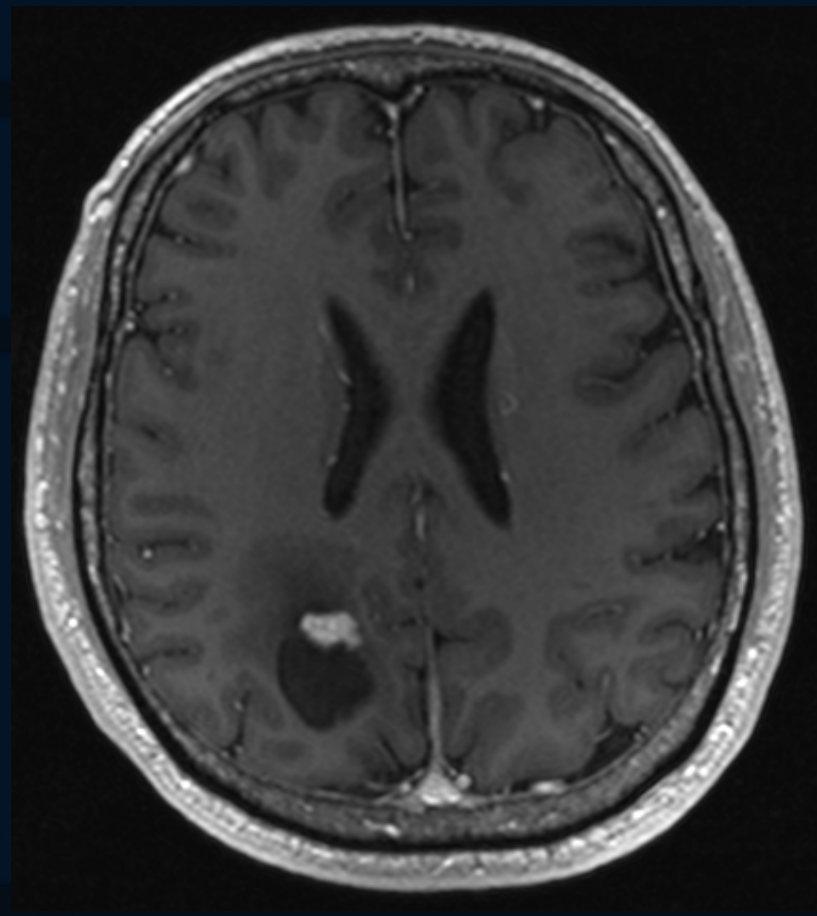

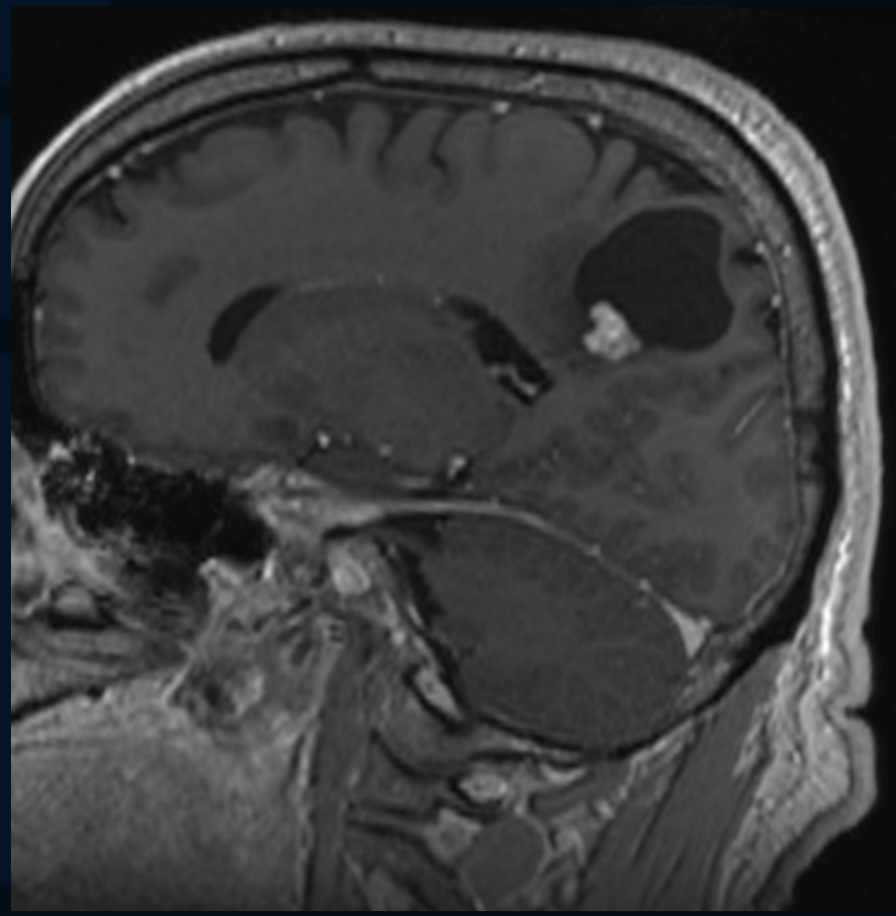

Imaging Discussion and Differential

- Well-demarcated 4.7 x 3.5 x 4.1cm (AP x TR x CC) parieto-occipital lesion centered predominantly within the white matter
- Mixed solid-cystic morphology
- Cystic component: T1 hypointense, T2 hyperintense, with FLAIR suppression
- Small associated enhancing mural nodule
- Mild surrounding vasogenic edema without significant mass effect or midline shift

Initial differential: primary glial neoplasm favored; hemangioblastoma and metastasis also considered

Management and Pathology

Management:

- Craniotomy and Surgical Resection
- Intraoperative interpretation favored astrocytoma with piloid features

Final Pathology:

- Hypercellular spindle-cell neoplasm arranged in intersecting fascicles
- Predominantly Antoni A morphology
- Strong S100 immunoreactivity; Substantial GFAP expression
- Very low proliferative index; No mitosis or necrosis

Final diagnosis: intraparenchymal schwannoma

Intraparenchymal Schwannoma: Imaging

- Rare CNS neoplasm arising within brain parenchyma without an identifiable nerve of origin
- Imaging appearance is ***variable*** and often can mimic other intra-axial tumors
- Reported findings include:
  - Solid or mixed solid-cystic morphology
  - Cystic lesions with enhancing mural nodules
  - Variable enhancement
  - Calcification and/or hemorrhagic products
  - Variable surrounding edema

Preoperative diagnosis is difficult because appearances overlap with more common intra-axial tumors

Outcome and Long Term Follow Up

- Excellent postoperative recovery without neurologic deficits or persistent presenting symptoms
- Immediate postoperative MRI demonstrated removal of the enhancing nodular component with partial decompression of the cystic component
- Serial MRI surveillance initially yearly and later extended to approximately every 3 years
- Stable CSF-signal postoperative cystic focus and minimal adjacent T2/FLAIR signal
- Published postoperative follow-up is generally limited, making prolonged serial imaging follow-up uncommon in the available literature.

No recurrent enhancing or nodular component over 13 years of follow-up

Take Home

- Intraparenchymal schwannoma is a rare benign CNS neoplasm without an identifiable nerve of origin, with fewer than 100 supratentorial cases identified in a recent systematic review.
- Imaging appearances are variable and may overlap with more common intra-axial neoplasms, making preoperative diagnosis challenging.
- Awareness is important despite difficult recognition given the generally favorable prognosis following resection
- Prolonged stability on serial MRI in this case contributes to the limited published literature on long-term follow up.

References

- Casadei GP, Komori T, Scheithauer BW, Miller GM, Parisi JE, Kelly PJ. Intracranial parenchymal schwannoma: a clinicopathological and neuroimaging study of nine cases. J Neurosurg. 1993;79(2):217-222. doi:10.3171/jns.1993.79.2.0217.

- Jimenez AE, Ellsworth H, Hargas G, Kaur G, Pan PC, McKhann GM. Supratentorial intraparenchymal schwannoma: Systematic review of the literature with an illustrative case. J Clin Neurosci. 2026;152:112164. doi:10.1016/j.jocn.2026.112164.

- Schmid S, Mirchia K, Tietze A, et al. VGLL fusions define a new class of intraparenchymal central nervous system schwannoma. Neuro Oncol. 2025;27(4):1031-1045. doi:10.1093/neuonc/noae269.

- Zagardo MT, Castellani RJ, Rees JH, Rothman MI, Zoarski GH. Radiologic and pathologic findings of intracerebral schwannoma. AJNR Am J Neuroradiol. 1998;19(7):1290-1293.