More Than a Headache: Imaging Findings of Choroid Plexus Carcinoma

Jasmine Clark | Meharry Medical College
Mohamed Eltilib, M.D. | UCHealth University of Colorado

MEHARRY
SCHOOL OF MEDICINE

Clinical Presentation

A 3-year-old male with no significant medical history presents to ED with his mother for a 2-week history of daily headaches causing irritability, vomiting, and balance issues. The headaches are worse in the morning and awake him from his sleep.

Imaging: CT

Axial CT

Large right hemispheric mass with associated obstructive hydrocephalus and midline shift.



Imaging: MRI

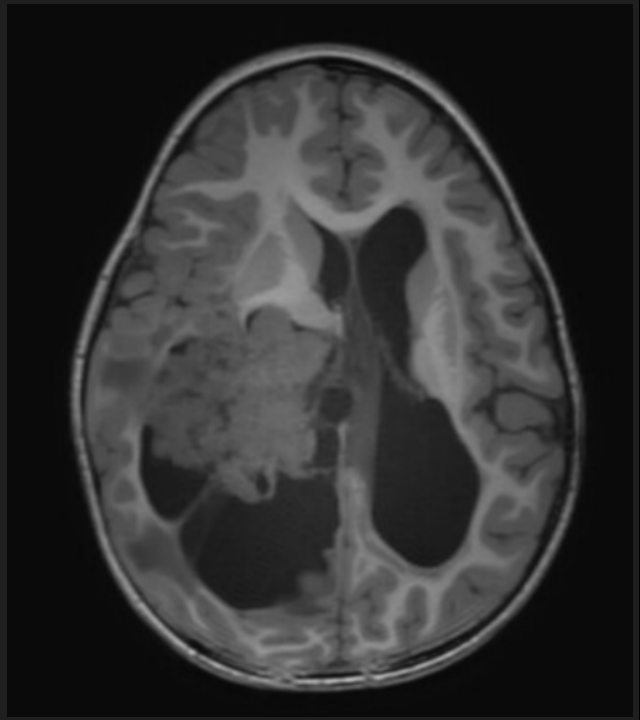

T1 Axial
Pre contrast

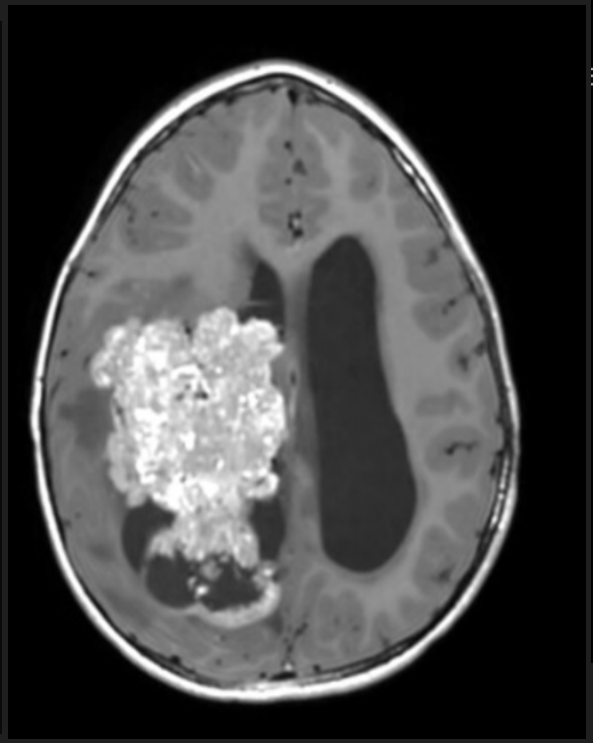

T1 Axial
Post contrast



T1 Sagittal
Post contrast

Imaging: MRI Cont.

MRI findings included a large mixed solid and cystic right hemispheric mass resulting in obstructive hydrocephalus due to mass effect on the tectal plate and cerebral aqueduct.

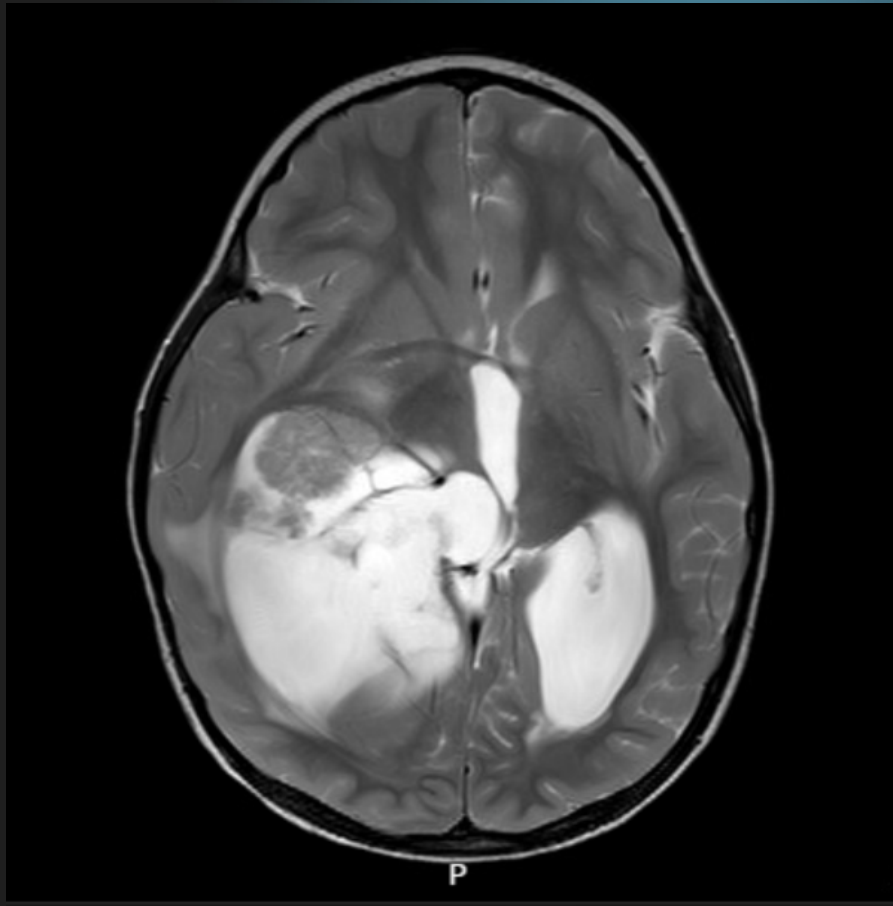

T2-Axial

Management

The management for this condition typically involves gross resection of the mass.

If the mass can be completely resected, there is typically no further treatment needed.

If the tumor is inoperable, management typically is centered around chemotherapy or CSF diversion via shunt placement.

Embolization of the tumor may also be used to slow the growth of the mass.

Genetic testing may also be indicated as choroid plexus carcinoma is associated with Li-Fraumeni syndrome.

Take Home Points

- Choroid plexus carcinoma is a rare, malignant brain tumor that begins in the choroid plexus.
- It is Classified as a WHO Grade 3 tumor and primarily affects young children under the age of five.
- Patients usually present with symptoms of increased intracranial pressure such as headaches, vomiting, irritability and seizures.

Outcome

The patient's treatment course has been complicated by seizure-like activity and a code-event with pulmonary hemorrhage requiring VA ECMO. He is currently being followed by palliative care for symptom and pain management.

Sources

Stanislavsky A, Silverstone L, Walizai T, et al. Choroid plexus carcinoma. Reference article, Radiopaedia.org (Accessed on 09 Aug 2026) https://doi.org/10.53347/rID-14202

Sun MZ, Oh MC, Ivan ME, Kaur G, Safaee M, Kim JM, Phillips JJ, Auguste KI, Parsa AT. Current management of choroid plexus carcinomas. Neurosurg Rev. 2014 Apr;37(2):179-92; discussion 192. doi: 10.1007/s10143-013-0499-1. Epub 2013 Sep 26. PMID: 24068529.

Thank you!