Beyond stroke: High-grade glioma presenting with unilateral deficits

Recognizing imaging features of subacute infarct mimics

Ian VanAntwerp DO

Sonia Gill MD

Froedtert & Medical College of Wisconsin

Clinical Presentation

- A 75-year-old male with no significant past medical history presented with right upper and lower extremity numbness
- Also reports right lower extremity “convulsions” over the past 3 weeks, initially lasting for a few minutes at a time to up to 20-30 minutes
- On the day of presentation, his right leg gave out causing the patient to fall

Initial Imaging

- MRI of the brain was preformed without contrast
- Increased T2/FLAIR signal predominately in the left paracentral lobule and perirolandic region, with additional involvement of the left middle frontal gyrus
- No restricted diffusion or susceptibility (SWI not shown)
- Increased attenuation on ADC



T2

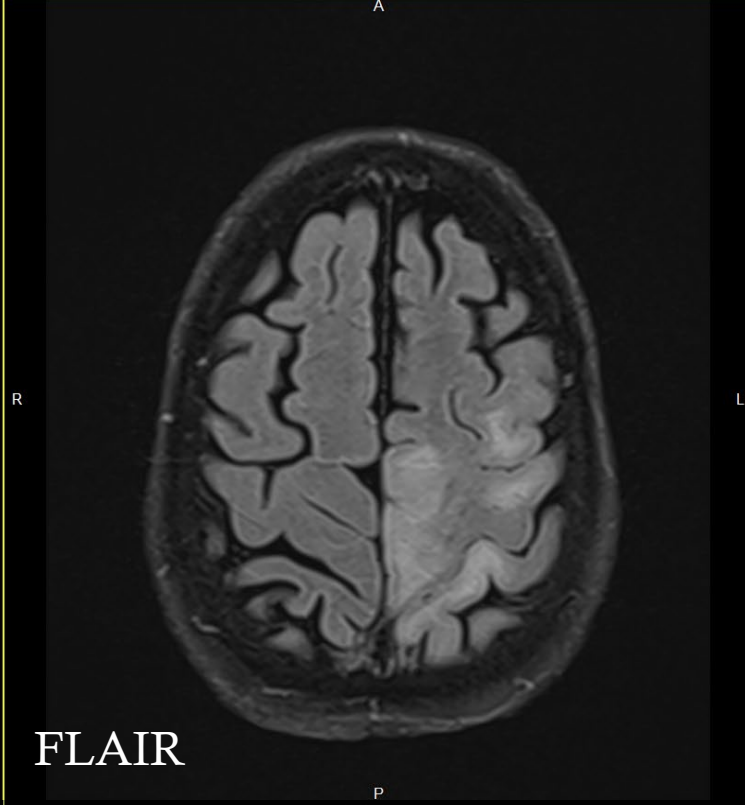

FLAIR

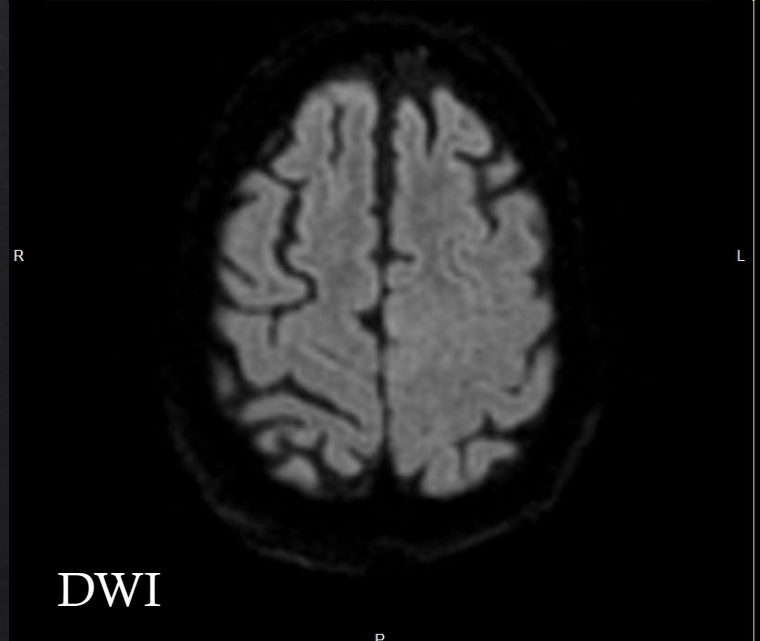

DWI

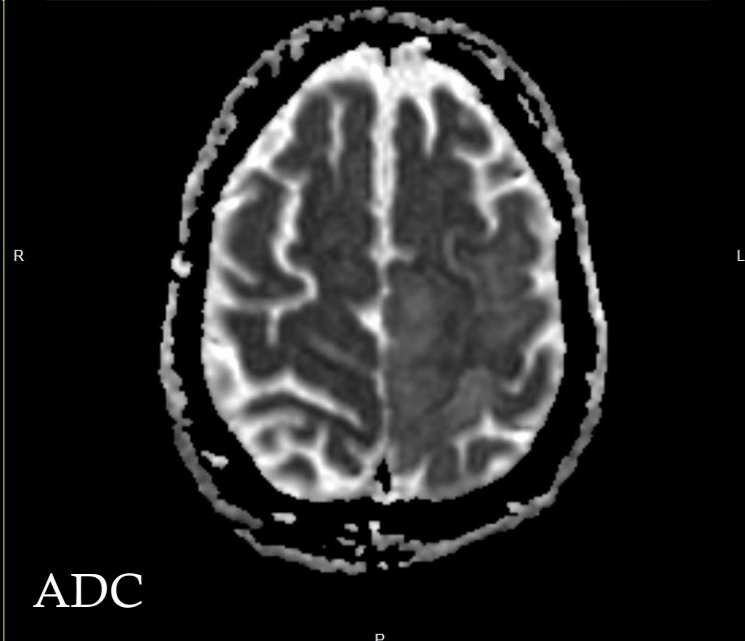

ADC

Imaging Discussion

- Gyral thickening (yellow arrows) in the area of T2/FLAIR hyperintensity with cortical involvement
- Sulcal effacement and narrowing (pink arrows) compared to the contralateral side
- Combination of T2/FLAIR hyperintensity and **cortical expansion** should prompt differential considerations beyond edema
- Impression: Differential diagnostic possibilities include a late subacute infarct, an infiltrative glioma, seizure related or encephalitis. Recommend contrast enhanced MRI and neurology consult.

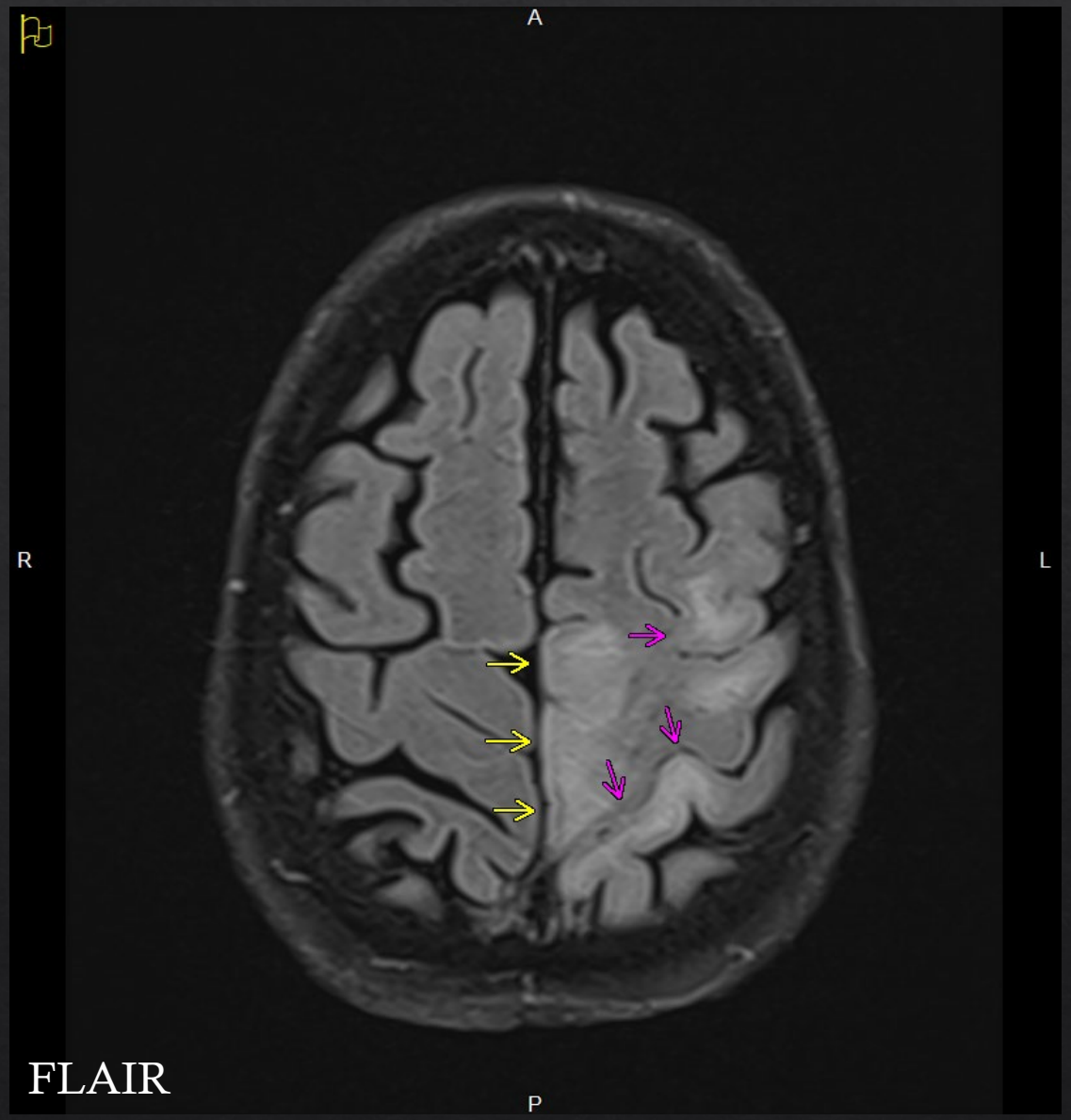

Initial Management

- Neurology concern for stroke, epilepsia partialis continua, or glioma.
- Keppra started for symptom management and the patient received a neurosurgery consult
- Contrast enhancement MRI and diffusion tensor imaging was preformed prior to biopsy

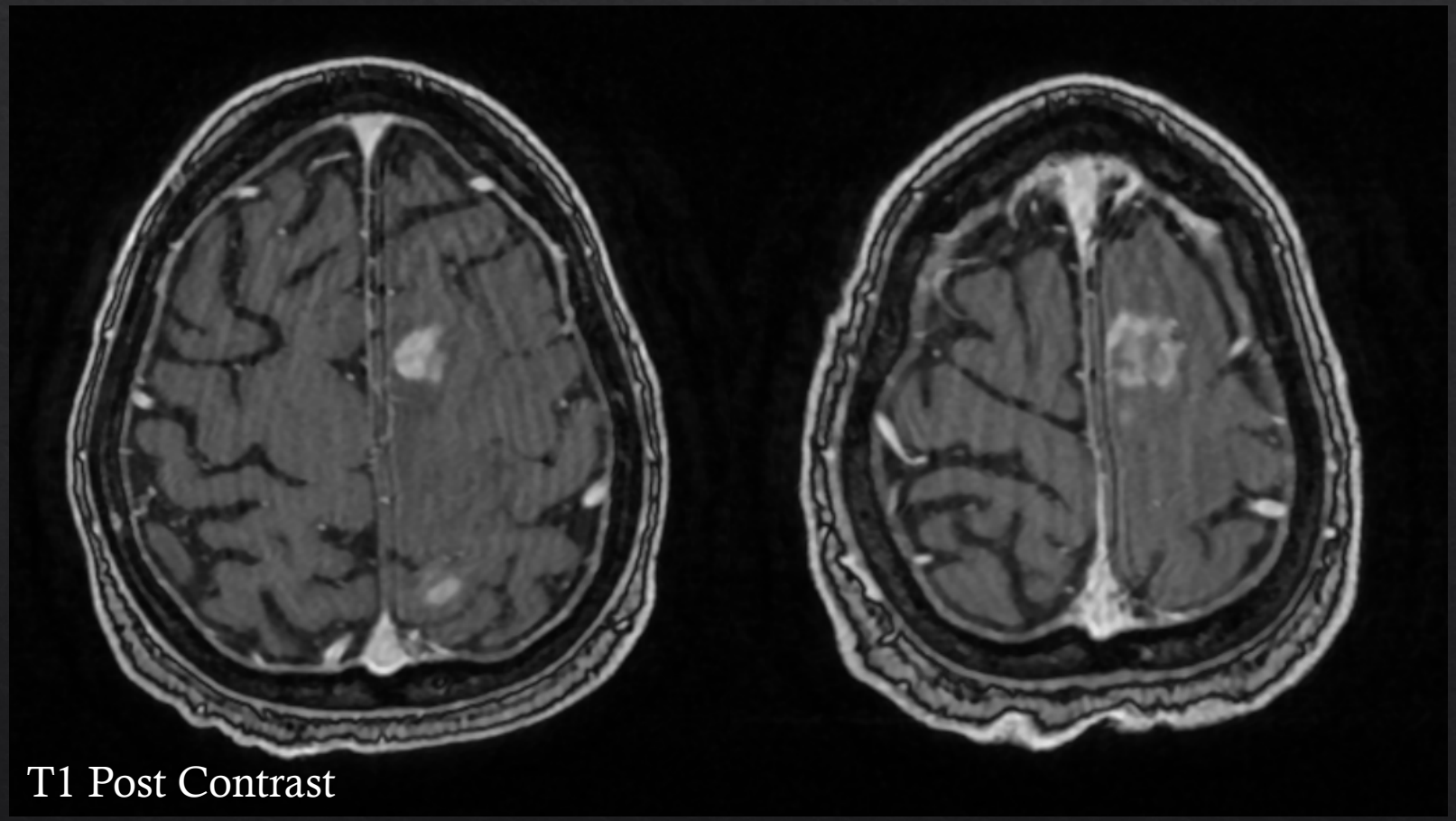

T1 Post Contrast

Heterogenous nodular enhancement predominantly throughout the left superior frontal gyrus and left precuneus

Diffusion Tensor Imaging

- Decreased fractional anisotropy largely throughout the region of T2/FLAIR hyperintensity involving the left medial, middle, and superior frontal gyri, left perirolandic region, and left precuneus.

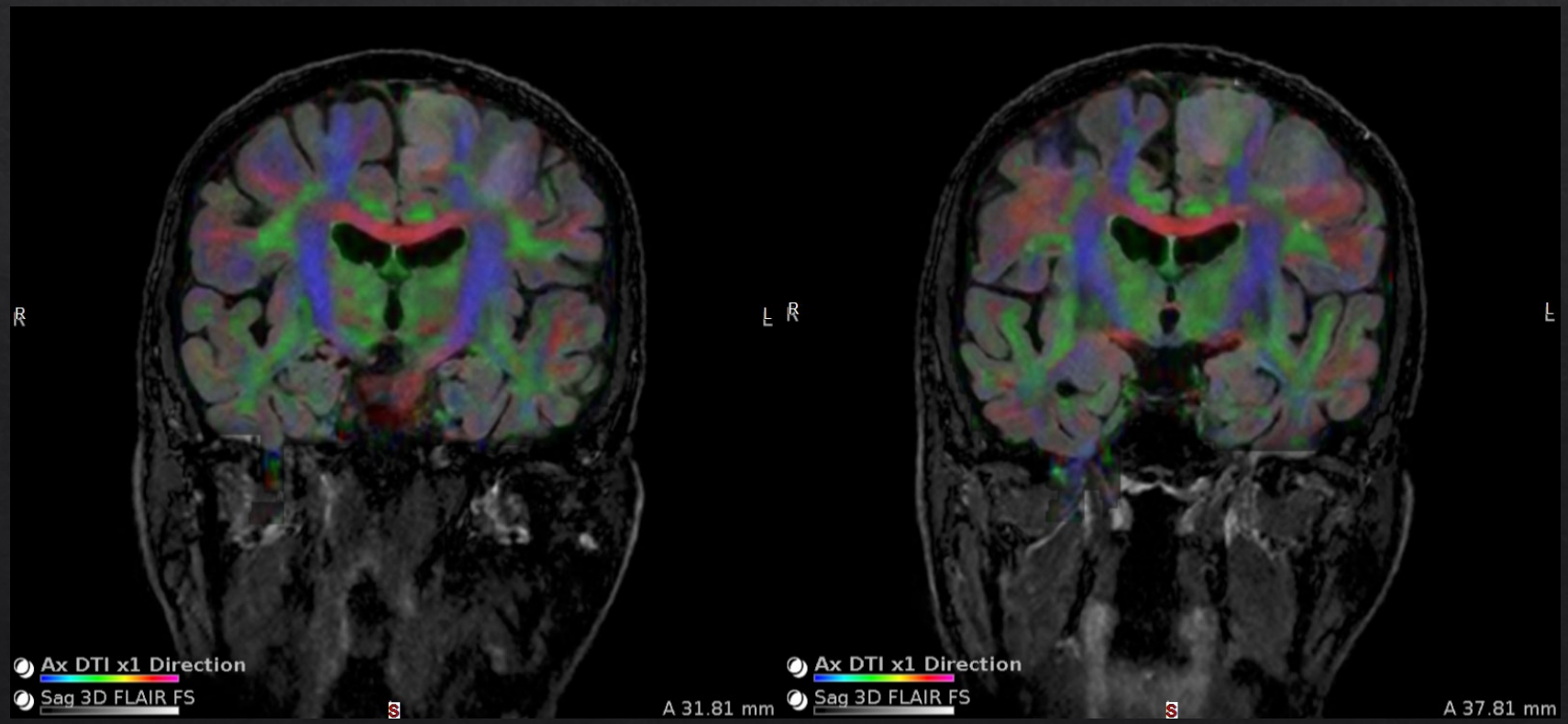

Management and Outcome

- Left frontoparietal biopsy performed with 8 core specimens
- Frozen pathology consistent with high-grade glioma with further analysis demonstrating **Glioblastoma, IDH wildtype**
- Deemed unresectable secondary to hemiplegia risk and the patient was established with oncology for chemotherapy and radiation

Microscopic Description

A - C: Sections of the left frontal lesion (A1, B1-2, C1) show cores of markedly hypercellular brain infiltrated by a glioma composed of anaplastic fibrillary astrocytes with mitoses, microvascular proliferation, and pseudopalisading necrosis. The tumor forms an infiltrating border with the adjacent brain.

Immunohistochemical studies show the following characteristics in the neoplastic cells (B1).

Olig2	Positive - subset
IDH1	Negative - wildtype
ATRX	Retained
P53	Wildtype

Appropriate controls are reviewed and found satisfactory.

Final Diagnosis

A - C: Brain, left frontal lobe, needle biopsy:
- Glioblastoma, IDH wildtype, CNS WHO grade 4. See Comment.

Discussion

- Glioblastoma, IDH-wildtype is a WHO grade 4 neoplasm with poorly differentiated astrocytic cells
- **Most common** malignant brain tumor in adults
- Usually occurs after age 40, with peak incidence between 55-75 years of age
- Slight male preponderance - M:F 3:2
- Median survival of 12-14 months, most patient's die within 15-18 months after chemoradiation
- Clinical presentation
  - Focal neurologic deficit
  - Seizures
  - Symptoms of increased ICP

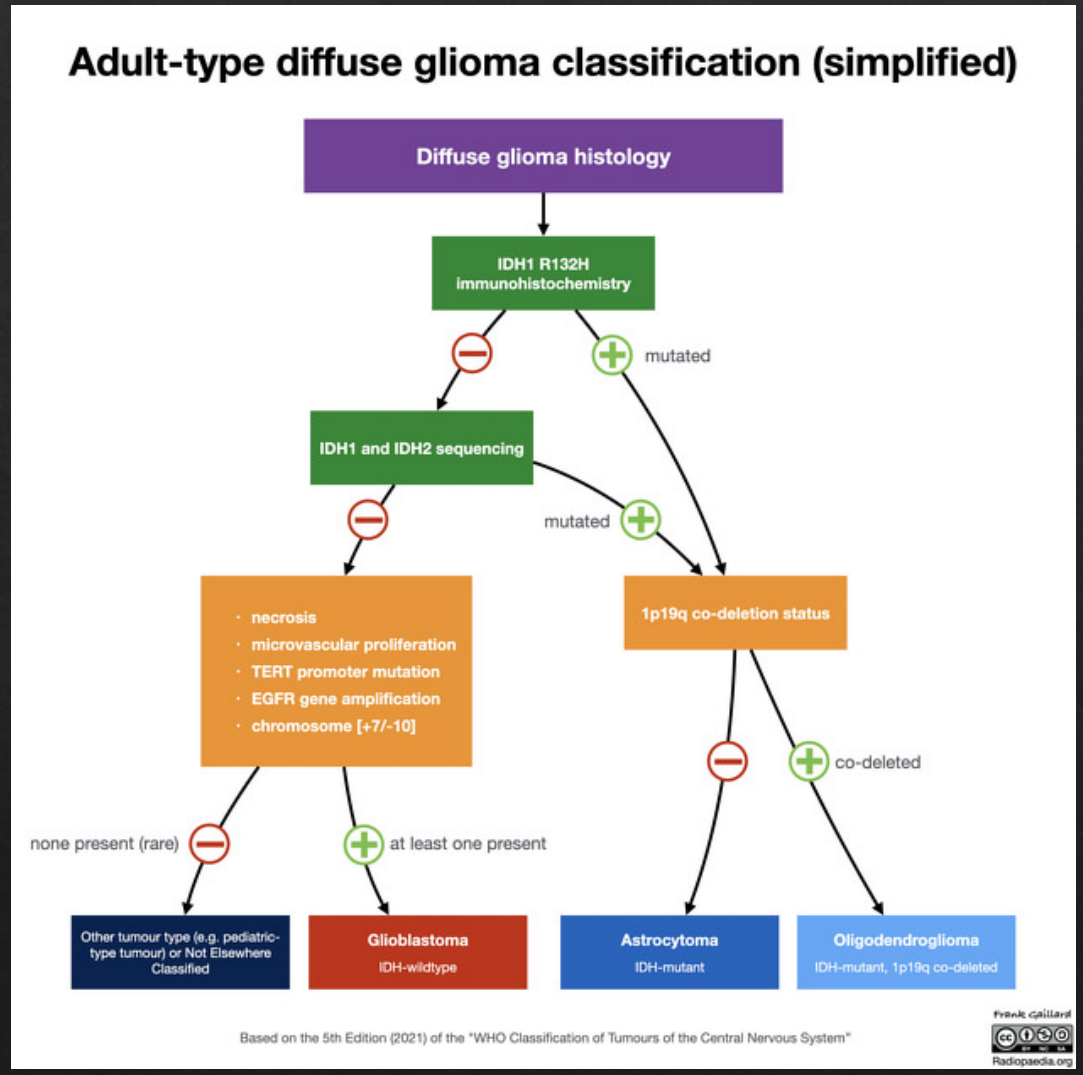

Glioblastoma, IDH-wildtype

- Diffuse, highly cellular WHO grade 4 neoplasm
- Irregular, diffusely infiltrating white matter mass with hemorrhage, central necrosis
  - Irregular thick rind of heterogenous enhancement
  - Less common – **solid, nodular, or patchy enhancement**
- Heterogenous T2/FLAIR hyperintensity +/- prominent peritumoral vasogenic edema
- IDH-wildtype and H3-wildtype and exhibits 1 or more of
  - Microvascular proliferation
  - TERT promoter mutation
  - EGFR gene amplification
  - +7/-10 chromosome copy number changes
- MGMT hypermethylation correlated with longer survival

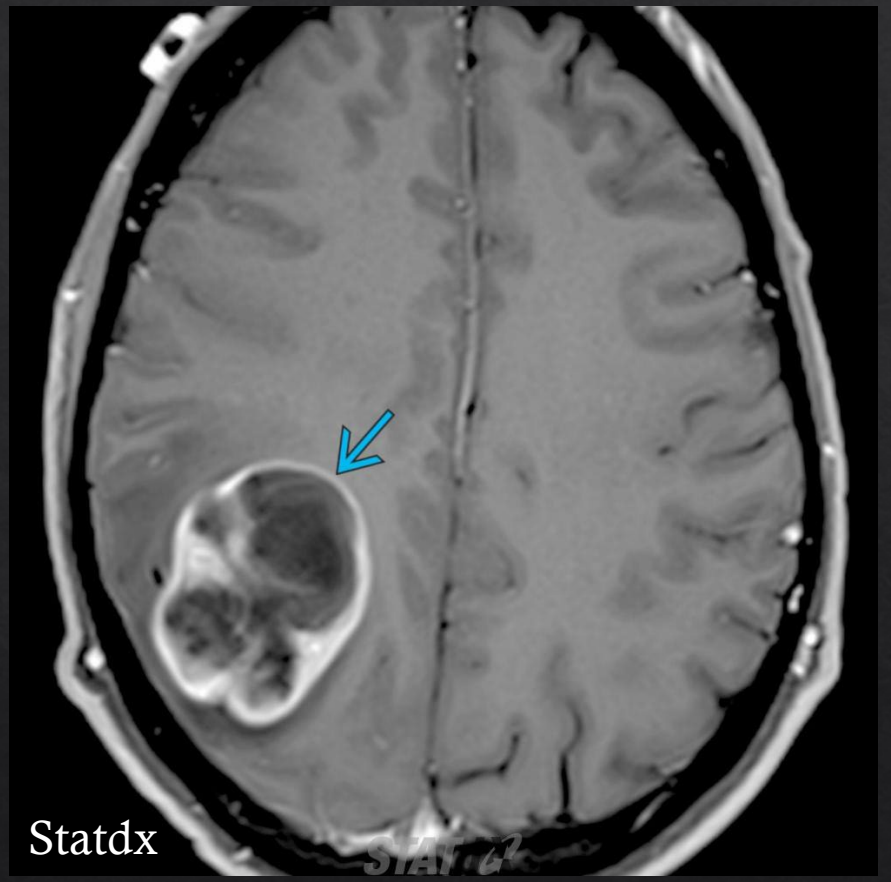

1- Regional Gray and White Matter

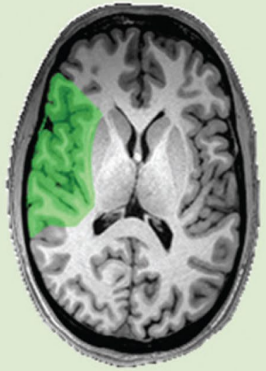

- Single Vascular Distribution Stoke*
- Seizures and Postictal Deficits
- Migraine Headache
- Primary Brain Tumors
- Hypoglycemia
- Transient Global Amnesia
- Herpes Simplex Encephalitis
- Venous Thrombosis

2- Cortical and Deep Gray Matter

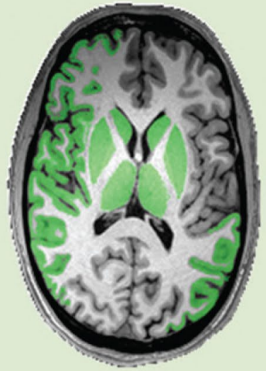

- Hypoxic-Ischemic Encephalopathy*
- Hepatic Encephalopathy
- Creutzfeldt Jakob Disease
- Eastern Equine Encephalitis
- Wernickes' Encephalopathy

3- Deep Gray Matter



- Penetrating Vessel Stroke*
- Hypoxic-Ischemic Encephalopathy*
- Carbon Monoxide Poisoning*
- Extrapontine Osmotic Myelinolysis
- Wernickes' Encephalopathy
- Creutzfeldt Jakob Disease
- Vigabatrin Toxicity
- Nonketotic Hyperglycemia
- Venous Thrombosis

4- White Matter

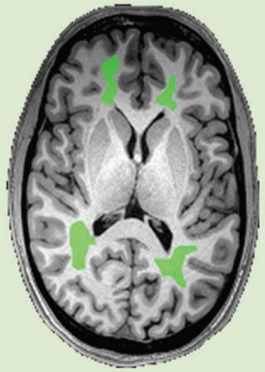

- CADASIL*
- Susac's Syndrome*
- Metronidazole Toxicity
- Methotrexate Toxicity
- Heroin leukoencephalopathy
- Demyelinating Diseases
- Cerebritis/Abscess

5- Multiple Scattered Foci

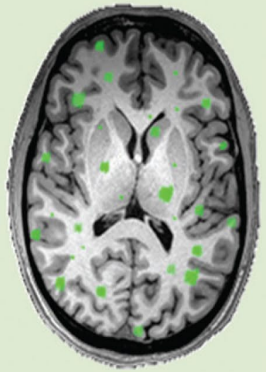

- Multiple Vascular Distribution Stroke*
- Diffuse Axonal Injury
- Fat Emboli
- Metastases

6- Border Zone Pattern

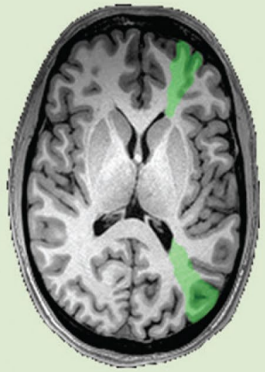

- Border Zone Stroke*
- Reversible Cerebral Vasoconstriction Syndrome (RCVS)*
- Moya-moya Disease*
- Posterior Reversible Encephalopathy (PRES)
- Hyperperfusion Syndrome

7- Splenial lesion

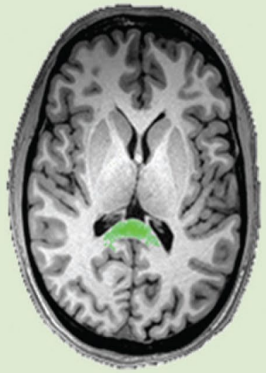

- Antiepileptic Medications
- Seizures
- Hypoglycemia
- Trauma
- Wernicke's encephalopathy
- Osmotic Myelinolysis
- Marchiafava–Bignami disease
- Radiation therapy
- Altitude sickness

Applied Radiology. Stroke differential diagnosis and mimics. (*) denotes ischemic causes.

Take Home Points

- High-grade gliomas can present with acute stroke-like symptoms, including focal neurologic deficits, making the initial clinical diagnosis challenging
- T2/FLAIR hyperintensity with cortical expansion should raise the concern for infiltrative neoplasm, especially when imaging findings or clinical presentation are disproportionate or atypical for infarction
- Diagnosis can be challenging in cases of late or delayed presentation, as both infiltrative neoplasm and subacute/chronic infarcts can lack diffusion restriction
- Radiologic-pathologic correlation is essential. When imaging is atypical, tissue diagnosis may ultimately be required
- Maintain a broad differential for stroke presentations with atypical imaging features

References

- Hilario A, Ramos A, Perez-Nuñez A et al. The Added Value of Apparent Diffusion Coefficient to Cerebral Blood Volume in the Preoperative Grading of Diffuse Gliomas. AJNR Am J Neuroradiol. 2012;33(4):701-7.
- Kamalian S, Boulter DJ, Lev MH, Gonzalez RG, Schaefer PW. Stroke differential diagnosis and mimics: Part 1. Applied Radiology. 2015;44(11):26-39.
- Kurokawa, R. et al. Major changes in 2021 World Health Organization classification of central nervous system tumors. *RadioGraphics* **42**, 1474–1493 (2022).
- Louis D, Perry A, Wesseling P et al. The 2021 WHO Classification of Tumors of the Central Nervous System: A Summary. Neuro-Oncology. 2021;23(8):1231-51.
- Molinaro A, Taylor J, Wiencke J, Wrensch M. Genetic and Molecular Epidemiology of Adult Diffuse Glioma. Nat Rev Neurol. 2019;15(7):405-17.
- Price M, Ballard C, Benedetti J et al. CBTRUS Statistical Report: Primary Brain and Other Central Nervous System Tumors Diagnosed in the United States in 2017-2021. Neuro Oncol. 2024;26(Supplement_6):vi1-vi85.
- Salzman K, Osborn A. Glioblastoma, IDH-wildtype. Last updated 0/21/25. https://app.statdx.com/document/glioblastoma-idh-wildtype/74717596-7450-4164-a9ae-860bd0228d54?
- Watanabe M, Tanaka R, Takeda N. Magnetic Resonance Imaging and Histopathology of Cerebral Gliomas. Neuroradiology. 1992;34(6):463-9.

Ian VanAntwerp DO

Contact: ivanantwerp@mcw.edu

Froedtert & Medical College of Wisconsin