Christian Cordon -Cano
Warren Sams
Kevin Hiatt

Neuroimaging Complications of Monoclonal Antibodies

Southeastern Neuroradiological Society Annual Meeting 2026

CTLA-4 Inhibitors

- Immunostimulating mAbs that inhibit CTLA-4.
- Common agents include Ipilimumab and Tremelimumab.
- Uses include malignant melanoma, as well as potential for metastatic renal cell carcinoma and prostate cancer
- For neuroradiology, most common AE is hypophysitis which occurs in about 10-18% of patients
- Symptoms that manifest from hypophysitis include headache, fatigue, adrenal insufficiency, temperature intolerance, insomnia, anorexia, and hallucinations
- This shows up on imaging as an enlarged pituitary gland, enlargement of the infundibulum, as well as loss of posterior pituitary signal on precontrast T1 weighted imaging
- Other non neuro related immune adverse effects include arthritis, hepatitis, dermatitis and colitis

CTLA-4 Inhibitors | Hypophysitis

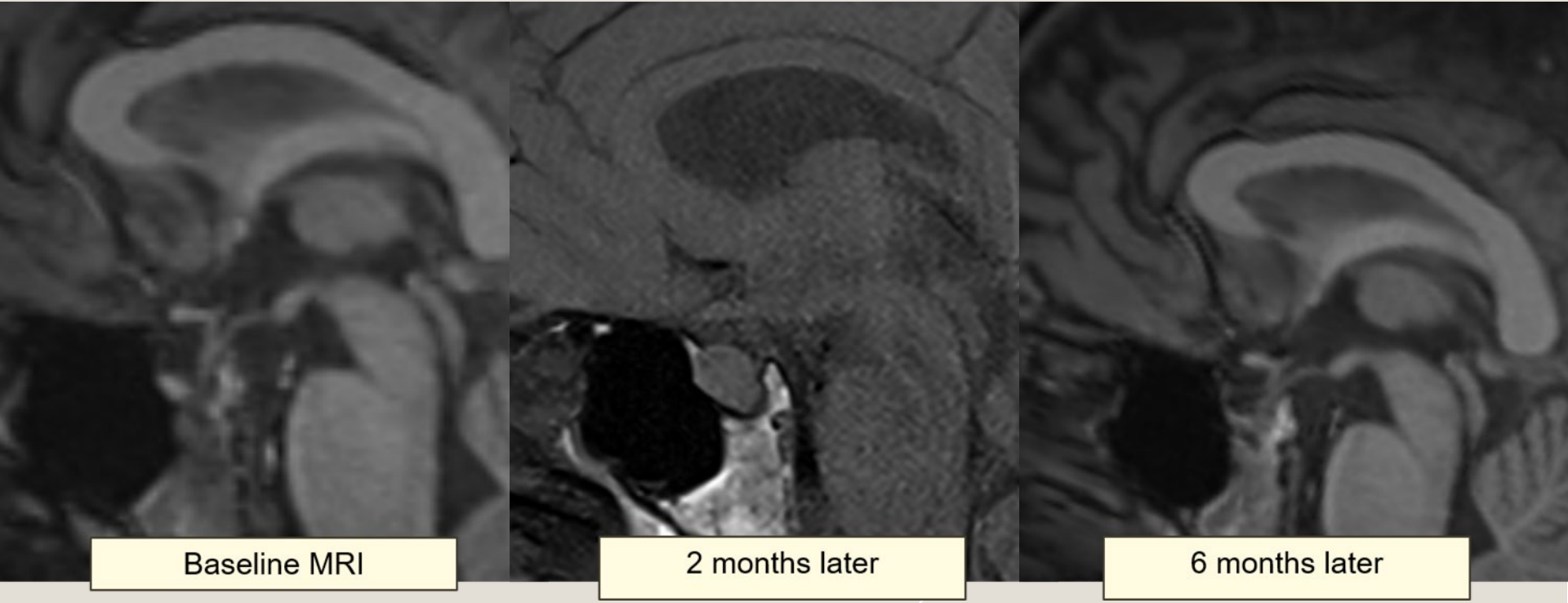

Compared to the baseline MRI, the pituitary gland markedly enlarged 2 months after starting therapy and returned to baseline size 6 months later.

Alpha/Beta Integrin Inhibitors

- Humanized mAbs targeting alpha 4 beta 1 and alpha 4 beta 7 integrins, which prevents inflammatory cells crossing the blood brain barrier, thus creating CNS immunosuppression
- Natalizumab is a common agent
- Typically used for MS and Crohn's Disease
- Main AE to look for is PML due to JC virus
- On MRI this appears as T2/FLAIR hyperintensities, with subcortical U - fiber involvement, that do not enhance. Over time, the lesions become hypointense on T1 and may present as a granular pattern. DWI initially is hyperintense, but as lesions regress DWI becomes more hypointense.
- If natalizumab is discontinued due to PML concerns, another AE to look for is rebound of MS
- On MRI, this will appear as new lesions that can be enhancing or non enhancing.

Alpha/Beta Integrin Inhibitors | PML

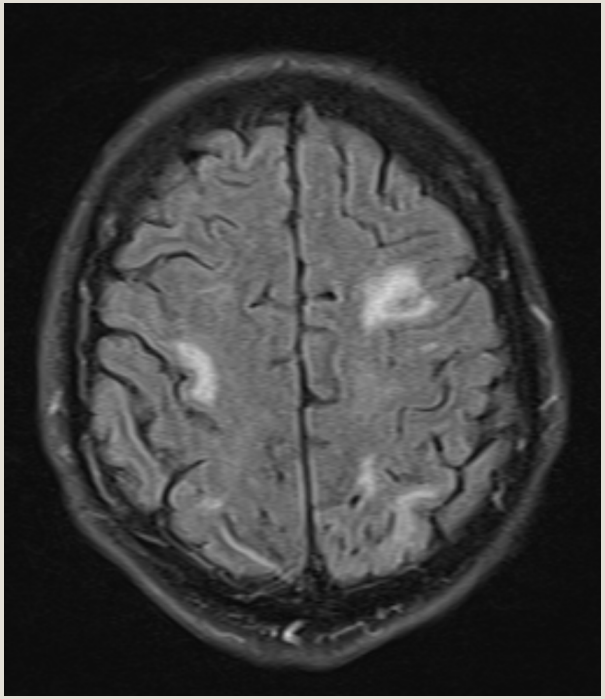

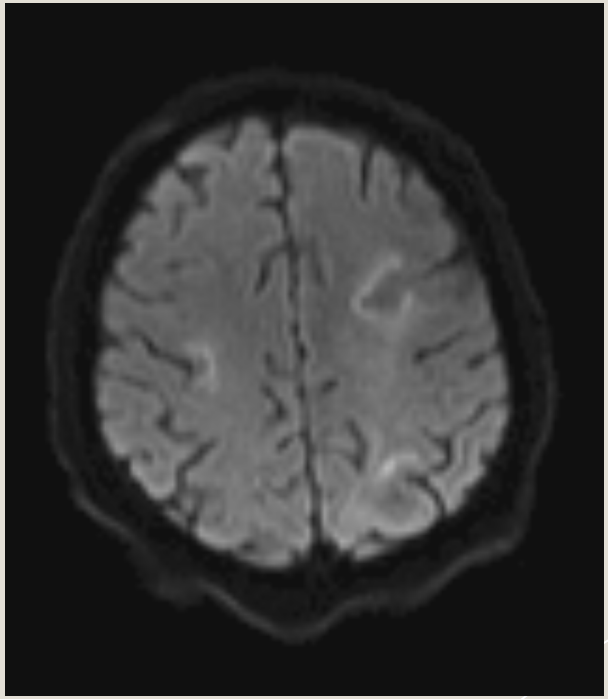

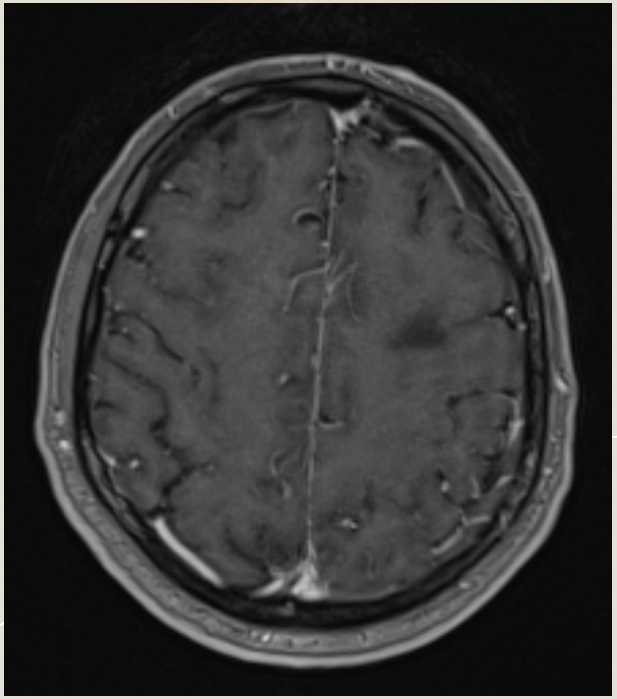

Multiple juxtacortical (involving the subcortical U-fibers) lesions involve both cerebral hemispheres asymmetrically with T2 (left image), leading edge restricted diffusion (center image), and no enhancement (right image), which imaging appearance is FLAIR hyperintense signal classic for PML.

Anti-Amyloid Monoclonal Antibodies

- Humanized mAb against amyloid beta
- Common agents include lecanemab and donanemab
- Primarily used in Alzheimer's disease and mild cognitive impairment
- Primary action is clearance of brain amyloid plaques (largely via microglial phagocytosis); binding to amyloid in cerebral vessel walls can compromise vessel integrity and vascular permeability, which leads to amyloid related imaging abnormalities (ARIA), specifically edema/effusion (ARIA-E) or microhemorrhages/superficial siderosis (ARIA-H)

ARIA-E

- On imaging, ARIA-E looks similar to vasogenic edema and is best seen on T2-FLAIR, typically in white matter but sometimes in the gray matter
- Lesions are generally found in the posterior brain region, with the most common lobes being the occipital and parietal lobes, followed by frontal and temporal lobes. Cerebellar involvement is less common
- ARIA-E lesions typically do not have well defined margins, but sometimes they can be more well defined
- Sometimes the edema can spread into the leptomeningeal space, and this can lead to a sulcal effusion that is also appreciated on T2-FLAIR

ARIA-E

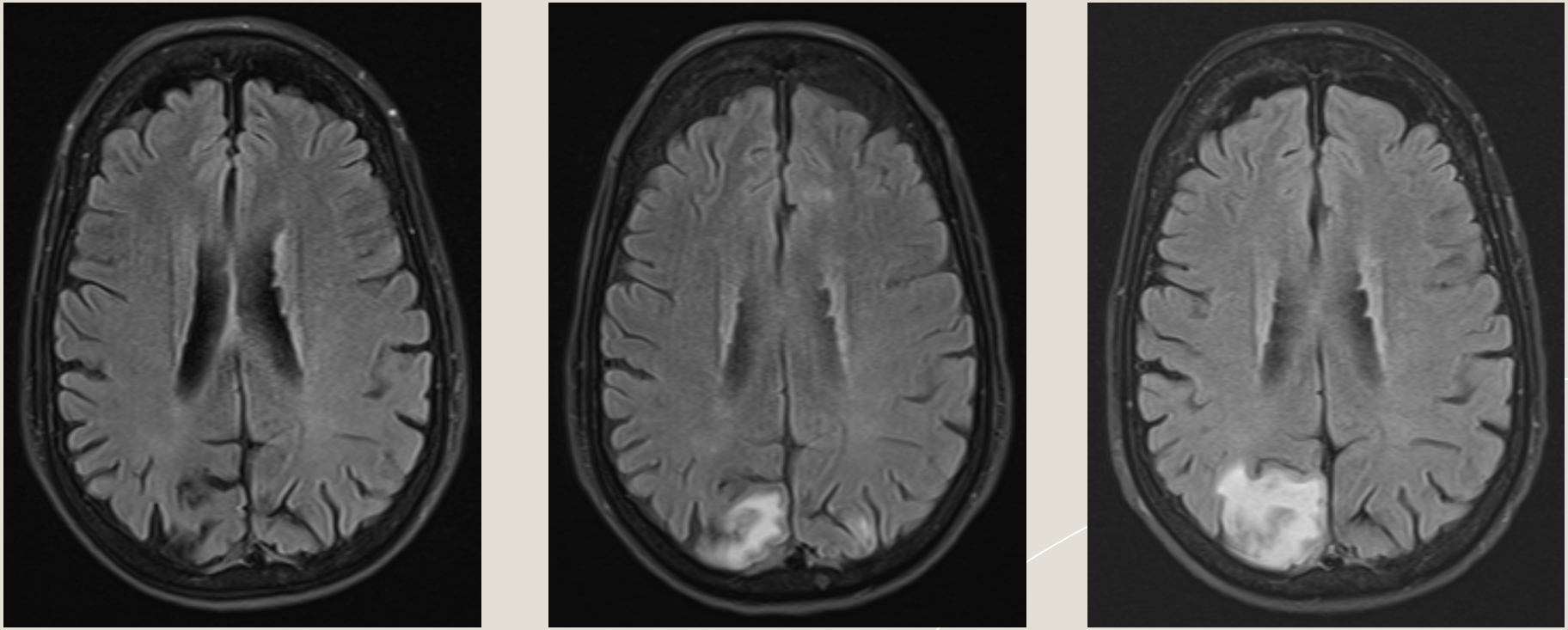

Axial T2 - FLAIR images from the baseline scan (left image), 3 months after starting therapy (center image), and 4 months after st arting therapy (right image) show development and worsening of areas of hyperintense signal in the right greater than left parieto - occipital white matter, co nsistent with ARIA - E.

ARIA-H

- On imaging this appears as microhemorrhages and siderosis, particularly on gradient and SWI
- Leaks into the intraparenchymal space lead to microhemorrhages that are hypointense and round, typically less than 10mm
- Leaks into the leptomeningeal space leads to superficial siderosis, and this presents as curvilinear hypointensities on the surface of the brain
- One rare imaging finding is lobar macrohemorrhage, which is defined as hemorrhage greater than 10mm in diameter

ARIA-H

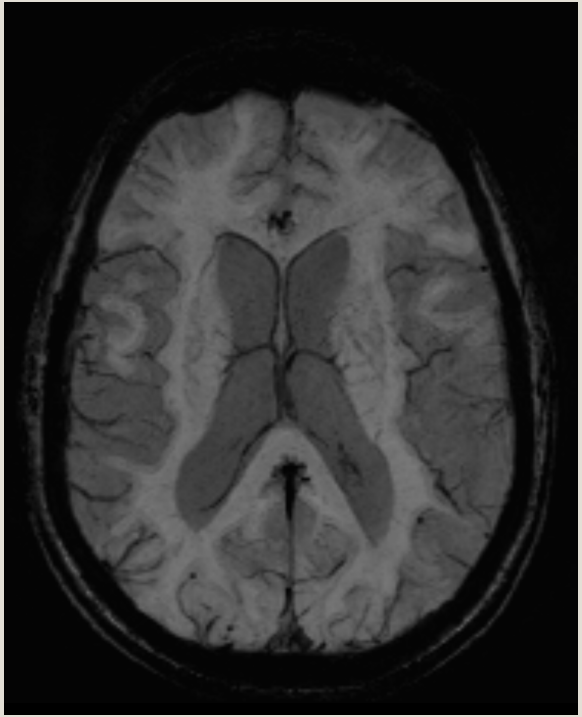

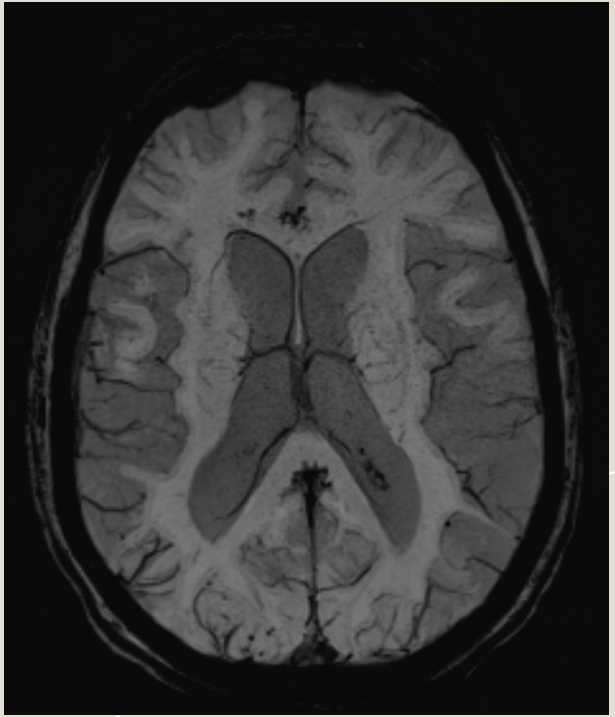

Axial SWI images from the baseline scan (left image) and 6 months after starting therapy (right image) show multiple new foci of hypointense signal in the right greater than left parieto-occipital regions, consistent with ARIA-H.

TNF-Alpha Inhibitors

- Human mAb against TNF - alpha
- Common agent is Adalimumab
- Typically used in inflammatory conditions such as IBD, RA, ankylosing spondylitis, and hidradenitis suppurativa.
- The main neuroimaging finding is new onset of demyelinating disease or exacerbation of existing demyelinating disease
- This appears on imaging as various demyelinating plaques with variable contrast enhancement
- TNF-alpha inhibitors can also cause optic neuritis

TNF-Alpha Inhibitors | Demyelination

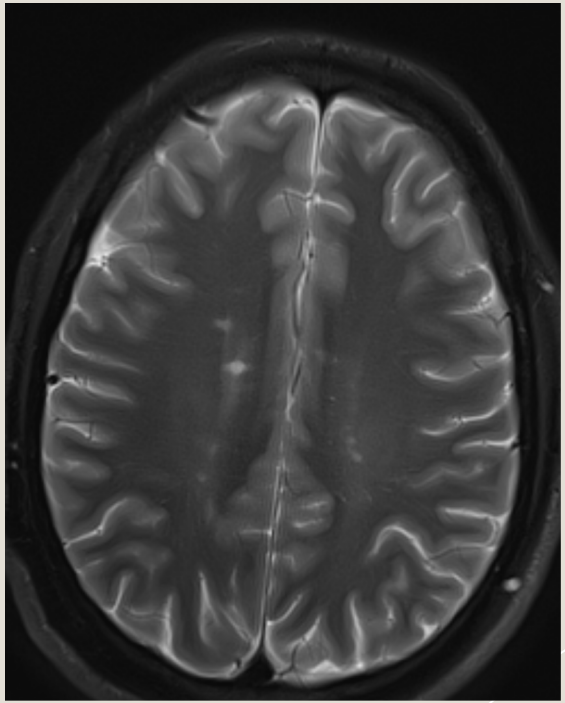

An axial T2 image demonstrates multiple periventricular hyperintense white matter lesions that developed on therapy, consiste nt with demyelinating disease.

CD20 Inhibitors

- Chimeric mAb against CD20
- Common agent is Rituximab
- Often used for non-Hodgkin lymphoma but can also be used for autoimmune conditions such as RA, granulomatosis with polyangiitis (GPA), and microscopic polyangiitis (MPA)
- The main complication associated with Rituximab is PML. On MRI this appears as T2-FLAIR hyperintensities, with subcortical U-fiber involvement, that do not enhance. Over time, the lesions become hypointense on T1 and may present as a granular pattern. DWI initially is hyperintense, but as lesions regress DWI becomes more hypointense.
- Another potential complication is Posterior Reversible Encephalopathy Syndrome (PRES), which typically appears on MRI as symmetric T2/FLAIR hyperintense vasogenic edema, predominantly in the bilateral occipital and posterior parietal subcortical white matter. CT has lower sensitivity

CD20 Inhibitors | PRES

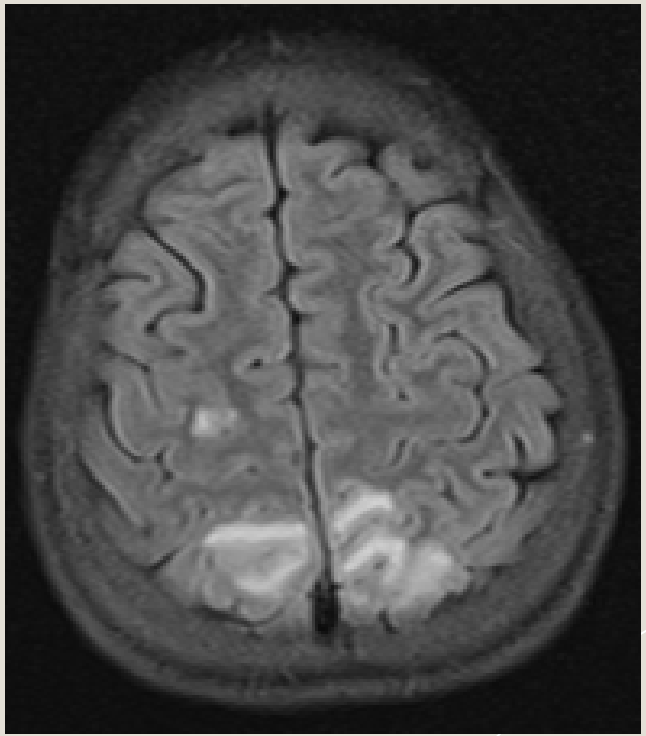

An axial T2 - FLAIR image demonstrates relatively symmetric hyperintense signal in the bilateral parieto - occipital white matter th at developed on therapy, consistent with PRES.

VEGF-A inhibitors

- Humanized monoclonal antibody that targets VEGF-A to inhibit angiogenesis and tumor neovasculature
- Common agent is Bevacizumab
- Use cases include metastatic colorectal cancer, metastatic RCC, NSCLC, recurrent glioblastoma, and cervical cancer
- Potentially linked to Posterior Reversible Encephalopathy Syndrome (PRES) - with or without HTN
    - On MRI T2-weighted sequence will show symmetric vasogenic edema predominantly in the bilateral occipital and posterior parietal subcortical white matter, CT has low sensitivity
- Increased risk for Intracranial Hemorrhage (ICH) at standard dose regimens
    - A dose-dependent relationship has been established with higher chances of ICH
- Increased risk for cerebrovascular events with malignant metastatic colorectal cancer

CD52 Inhibitors

- Humanized monoclonal antibody that targets CD52
  - Common Agent is Alemtuzumab
  - Used in Relapsing - Remitting Multiple Sclerosis (**RRMS**) and historically used in CLL and is used off label for T-cell prolymphocytic leukemia (T-PLL) with very high CD52 expression
- Eosinophilic CNS vasculitis that can present as seizures with multifocal T2/FLAIR lesions
  - Can mimic inflammatory demyelination, biopsy to confirm
- Mild, but still significant increased risk of PML
  - Keep in mind for new enhancing or nonenhancing subcortical/juxtacortical lesions with diffusion restriction

C5 Inhibitors

- Humanized mAb against C5
- Common agent is Eculizumab
- Typically used for Paroxysmal Nocturnal Hemoglobinuria (PNH) and Hemolytic Uremic Syndrome (HUS)
- As a result of targeting C5, eculizumab leads to higher risk of infection with encapsulated bacteria such as Neisseria Meningitidis, leading to meningitis/meningoencephalitis
- On imaging, meningitis initially may not show any abnormalities. However, over time linear pachymeningeal or leptomeningeal hyperintensity is present on FLAIR imaging, as well as potential hydrocephalus.
- When using eculizumab for HUS, imaging may show cerebral white matter and basal ganglia restricted diffusion. However, this is due to HUS not eculizumab and the imaging findings will go away after resolution of HUS.

PD-1/PDL1 Immunotherapy Inhibitors

- Immune - Checkpoint inhibitors that are used for a multitude of cancers, including NSCLC, renal cell carcinoma, urothelial carcinoma and triple negative breast cancer
- **Pembrolizumab** and **Nivolumab** (PD-1) have associations with immune-related encephalitis, which presents as T2/FLAIR hyperintensities in the medial temporal lobes or diffusely in the cortical regions, with CT having low sensitivity. There is also a correlation with CNS vasculitis that will show multifocal T2/FLAIR hyperintensities in the white matter and become a mimicker for ischemic stroke
- **Atezolizumab** (PD-L1) is used less frequently, and will show a similar side effect profile to the PD1 inhibitors, with the exception being that they have a higher rate of PNS neuropathies

PD-1/PDL1 | Encephalitis

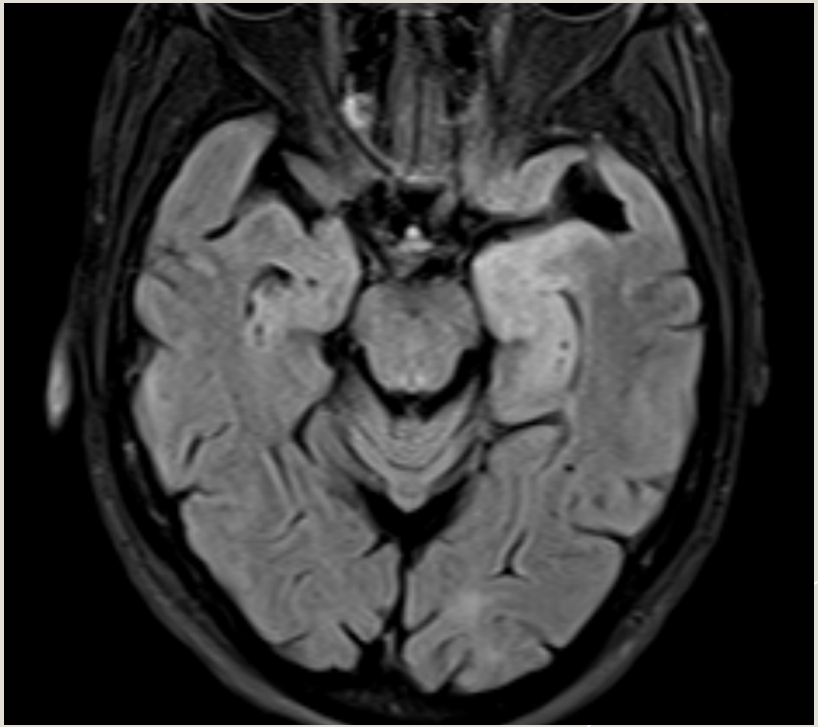

An axial T2 - FLAIR image demonstrates abnormal hyperintense signal affecting the left greater than right mesial temporal lobes, c onsistent with encephalitis.

References

- Alsufayan R, Guenette JP, Kim E, et al. Monoclonal antibodies: what the diagnostic neuroradiologist needs to know. *AJNR Am J Neuroradiol.* 2023;44(12):1358-1366. doi:10.3174/ajnr.A7974
- Berz AM, Hanania AN, Bedi H, et al. Imaging assessment of toxicity related to immune checkpoint inhibitors. *Front Immunol.* 2023;14:1133207. doi:10.3389/fimmu.2023.1133207
- Geocadin RG. Posterior reversible encephalopathy syndrome. *N Engl J Med.* 2023;388(23):2171-2178. doi:10.1056/NEJMra2114482
- Kurokawa R, Yamaguchi S, Nii K, et al. Dural and leptomeningeal diseases: anatomy, causes, and neuroimaging findings. *Radiographics.* 2023;43(9):e230039. doi:10.1148/rg.230039
- Leach OA, Hilton DA, Adams W, Love S, Straukiene A. Alemtuzumab-related eosinophilic central nervous system vasculitis. *Mult Scler J.* 2020;26(12):1602-1606. doi:10.1177/1352458519898113
- Socié G, Caby-Tosi MP, Marantz JL, et al. Eculizumab in paroxysmal nocturnal haemoglobinuria and atypical haemolytic uraemic syndrome: 10-year pharmacovigilance analysis. *Br J Haematol.* 2019;185(2):297-310. doi:10.1111/bjh.15790
- Vogrig A, Fouret M, Joubert B, et al. Central nervous system complications associated with immune checkpoint inhibitors. *J Neurol Neurosurg Psychiatry.* 2020;91(7):772-778. doi:10.1136/jnnp-2020-323055
- Wang GX, Kurra V, Gainor JF, et al. Immune checkpoint inhibitor cancer therapy: spectrum of imaging findings. *Radiographics.* 2017;37(7):2132-2144. doi:10.1148/rg.2017170085
- Wick W, Gorlia T, Bendszus M, et al. Neurological sequelae of cancer immunotherapies and targeted therapies. *Lancet Oncol.* 2016;17(12):e529-e541. doi:10.1016/S1470-2045(16)30571-X
- Zuo PY, Chen XL, Liu YW, Xiao CL, Liu CY. Increased risk of cerebrovascular events in patients with cancer treated with bevacizumab: a meta-analysis. PLoS One. 2014 Jul 15;9(7):e102484. doi: 10.1371/journal.pone.0102484