From Nerve Sheath to Thoracic Mass

Bryan Chan, PGY 4

Dr. Paul Lee





DONALD AND BARBARA
ZUCKER SCHOOL of MEDICINE
AT HOFSTRA/NORTHWELL®

Background

- Schwannomas are benign tumors originating from Schwann cells in the peripheral nerve sheaths
- MRI provides the most sensitive and specific imaging modality
- Typically T1 hypo to isointense, T2 hyperintense with heterogeneous enhancement
- Lobulated or dumbbell shape due to growth extending out of the spinal foramen
- Patients often present late in the disease course due to slow growth and nonspecific symptoms

Clinical Presentation

- 35 y/o female presents to outpatient pulmonology clinic for chronic cough persisting for eight months. Patient also reports new episodes of shortness of breath with exertion.
- She initially attributed these symptoms to lingering effects of previous COVID infection, but symptoms worsened over the past few months.
- No personal history of smoking, radiation, or family history of cancer.
- Vital signs were stable. Patient was saturating 99% on room air. Lungs were clear to auscultation.
- Patient was initially treated with albuterol and cough suppressants without resolution of symptoms after two weeks. A chest-xray was subsequently ordered.

Imaging Findings: Chest X-ray

- Initial chest x-ray revealed right upper lobe opacification
- There is a curvilinear well-delineated border inferiorly (yellow arrows) and an indistinct border superiorly (red arrow), consistent with an incomplete border sign and suggestive of an extrapulmonary lesion
- The trachea is also compressed and deviated towards the left (black arrow)

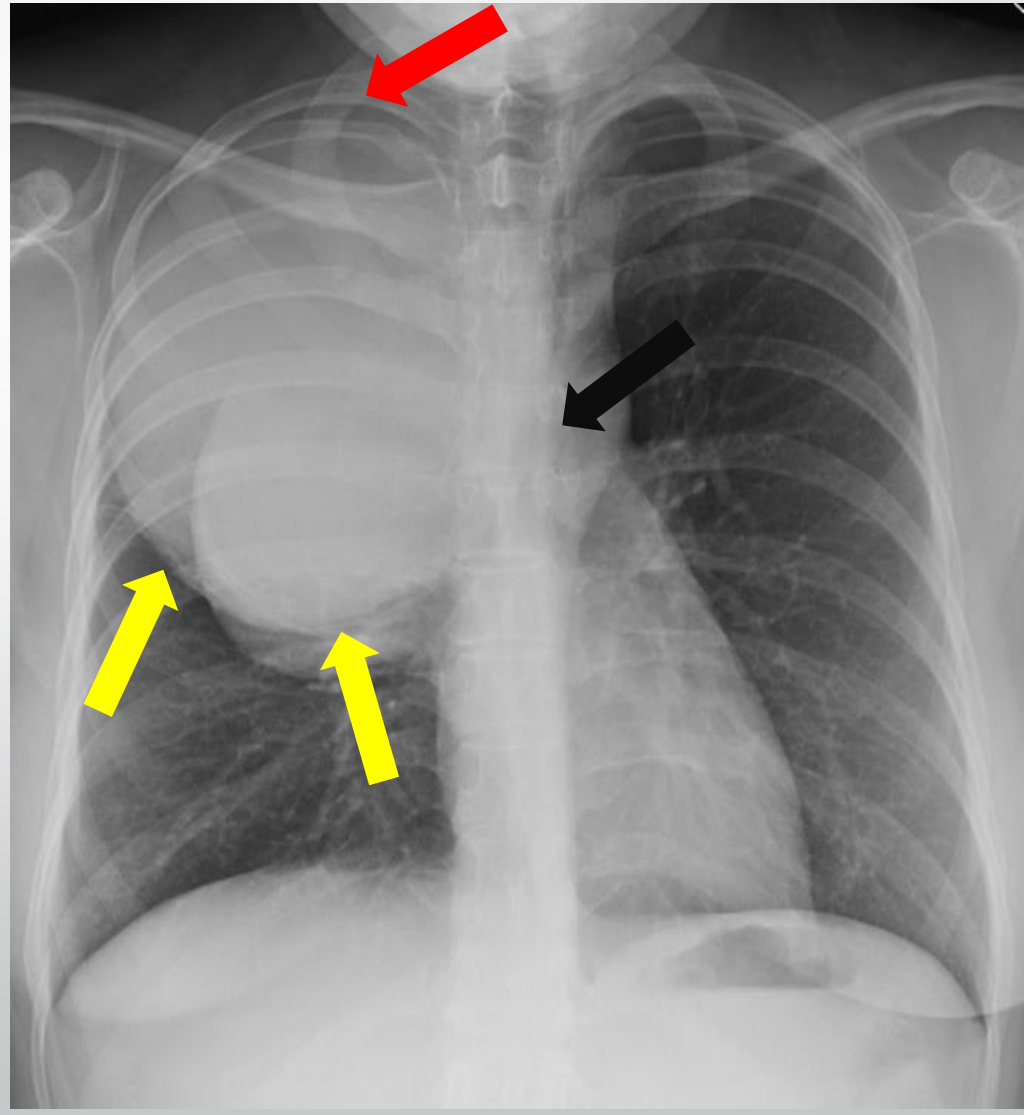

Imaging Findings: CT Chest & PET/CT

- A CT chest was ordered for further evaluation
- CT chest coronal (Figure A) and axial (Figure B) views show a large bilobed mass measuring up to 14 cm with tracheal compression and deviation at the level of the aortic arch (red arrows)
- FDG PET/CT shows avid FDG uptake (Figure C)

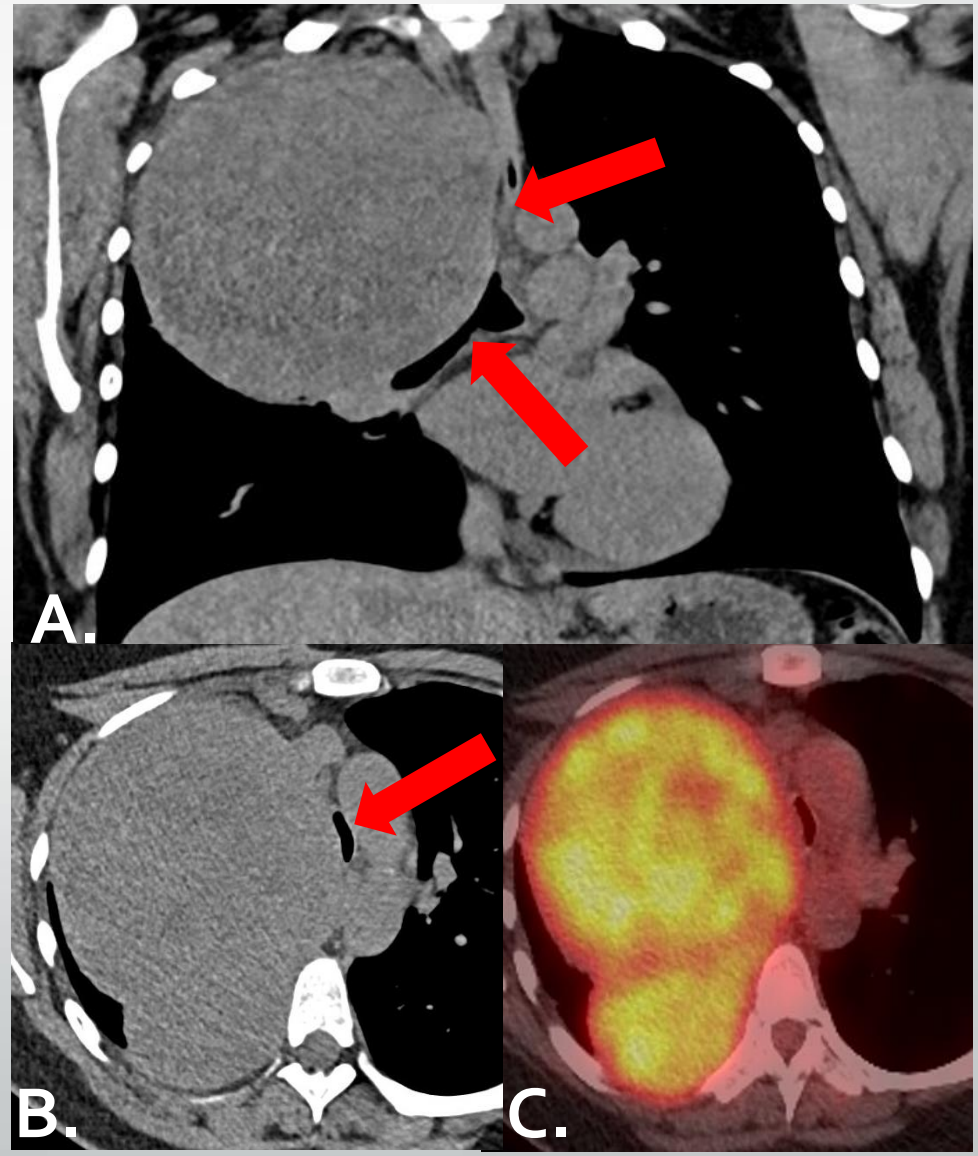

Additional Pertinent Positives

- Sagittal reformat better illustrates the lesion likely arising from the right T3-T4 neural foramen which is enlarged (Figure A, red arrow).
- Figure B- Bone window highlights smooth bony thinning of the posteromedial right third and fourth ribs (yellow arrows)
- These findings are all suggestive of a neurogenic origin lesion
- Other differential diagnoses, although less likely, include: fibrous tumor of the pleura and sarcoma

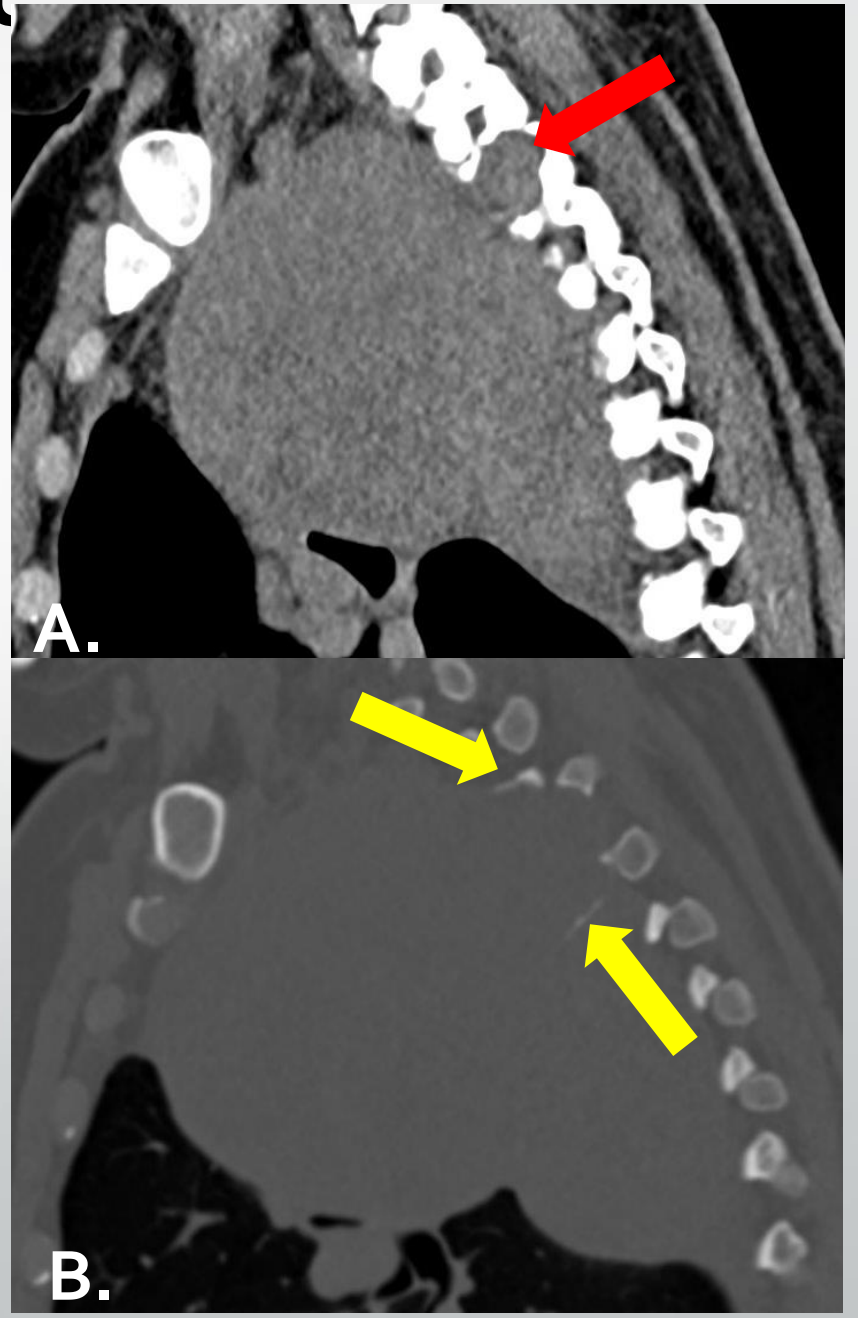

Imaging Findings: MRI

- Figures A & B: Axial T1 pre and post contrast respectively demonstrates heterogeneous enhancement. There is mass effect with compression of the trachea (red arrow)
- Figure C: MRI thoracic spine Axial T2 sequence with a heterogeneous lesion abutting the thecal sac and slightly displacing it towards the left (red arrow). There is smooth bony scalloping of the T3 vertebral body (yellow arrow)
- Figure D: MRI thoracic spine Sagittal T1 post contrast again shows heterogeneous enhancement. The lesion is clearly visualized arising from the right T3-T4 neural foramen with enlargement (red arrow).

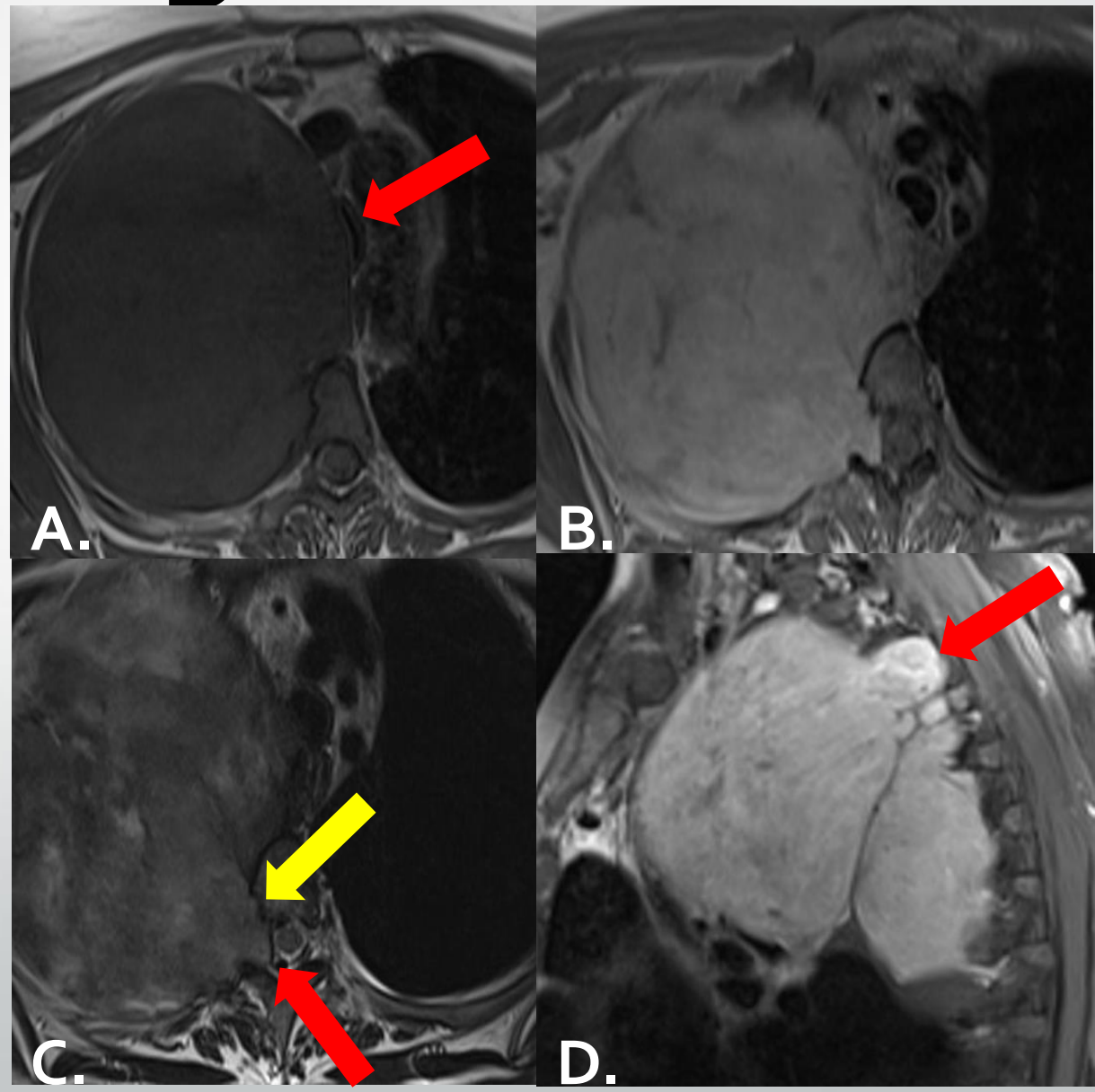

Management

- Multidisciplinary teams were involved in this patient's care.
- Interventional radiology was consulted for biopsy, which was consistent with a schwannoma.
- A two-day operation was performed with T3 laminectomy, ligation of the right T3 nerve root, and T3-T4 posterolateral fusion on day 1 by neurosurgery.
- This was followed by bronchoscopy, right thoracotomy, and excision of the right chest schwannoma by cardiothoracic surgery

Outcomes

- Post-operative course was uneventful
- Patient had routine follow-up after discharge
- Her cough has resolved and follow-up scans have been negative for recurrence

Take Home Points

- Schwannomas vary significantly in their location, appearances, and clinical presentations
- Due to slow growth and vague symptoms, these tumors can grow to a large size prior to being discovered
- Knowledge of key characteristic features is essential to formulating an accurate differential diagnosis and leading to timely referral and treatment

References

- Pavlus J, Carter B, Tolley M, Keung E, Khorashadi L, & Lichtenberger J. Imaging of Thoracic Neurogenic Tumors. 2016. American Journal of Roentgenology. 207(3): 552-561.

- Saleemi M, Abdelwahab A, Abdelwahab M, & George K. A case of a giant thoracic schwannoma. 2022. Surg Neurol Int. 13(188).

Thank You!

Bryan Chan, PGY 4
Bchan11@northwell.edu

Dr. Paul Lee
Plee2@northwell.edu

Northwell Health®

DONALD AND BARBARA ZUCKER SCHOOL of MEDICINE AT HOFSTRA/NORTHWELL®