Imaging Findings and Endovascular Management of a Cognard Type III Dural Arteriovenous Fistula.

2026 SENRS Annual Meeting

Arjun Ahuja, MD; Abrar Khaja, MD; Ashna Yalamanchi MD; Parinda Shah, MD

Advocate Illinois Masonic Medical Center, Chicago, IL

Clinical Presentation

88-year-old female presented to the ED with acute onset of dizziness, increased confusion, and weakness.

PMHx of HTN, DM, and dementia.

Initial Imaging: CT Head and CTA Head and Neck

CT Head

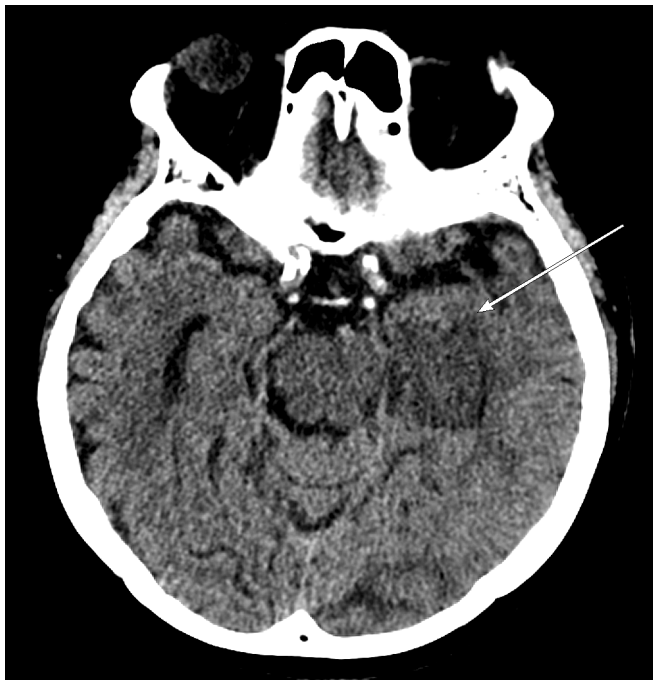

- Axial slice shows mildly expansile areas of hypoattenuation in the left cerebellum and the left temporo-occipital region, suggestive of cerebral edema.

CTA Head and Neck

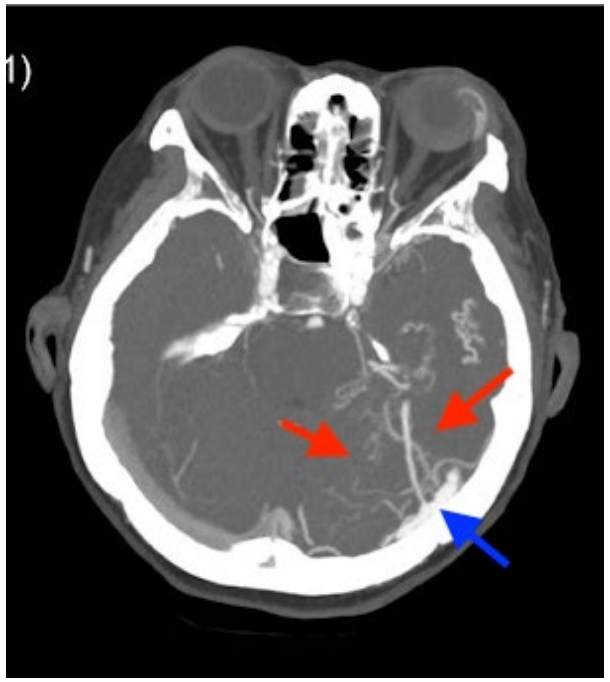

- Axial MIP reconstruction image shows extensive tortuous left posterior cortical veins (red arrows) with asymmetric early enhancement of an irregular distal left transverse-sigmoid sinus (blue arrow) (Figure 1).
- These findings were concerning for a dural arteriovenous fistula.

MRI Brain with and without contrast

- Axial FLAIR slices demonstrate areas of mildly expansile hyperintensity in the left cerebellum, left occipital lobe, and left medial temporal lobe (Figure 2a-2b).

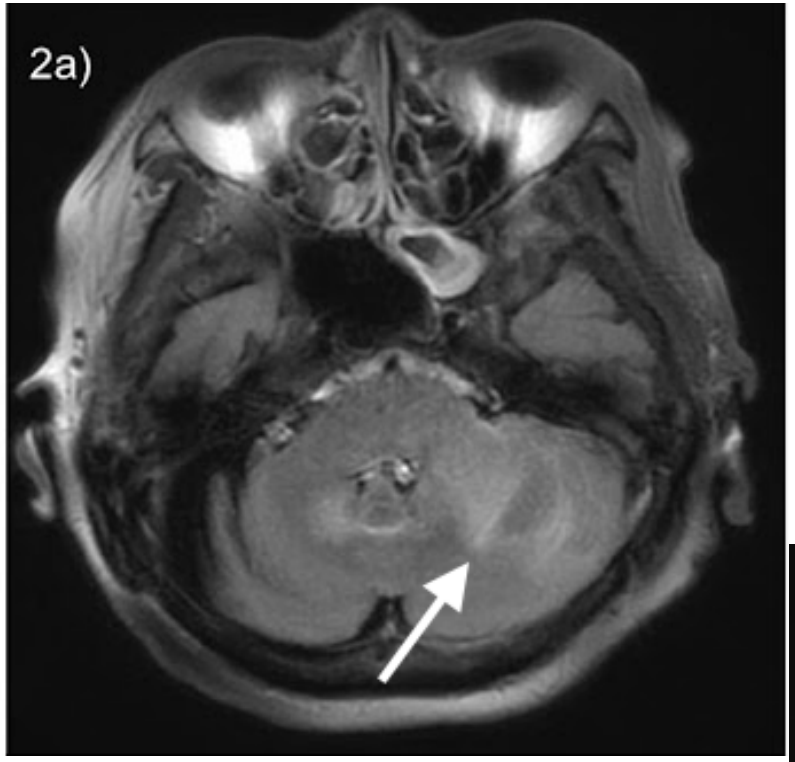

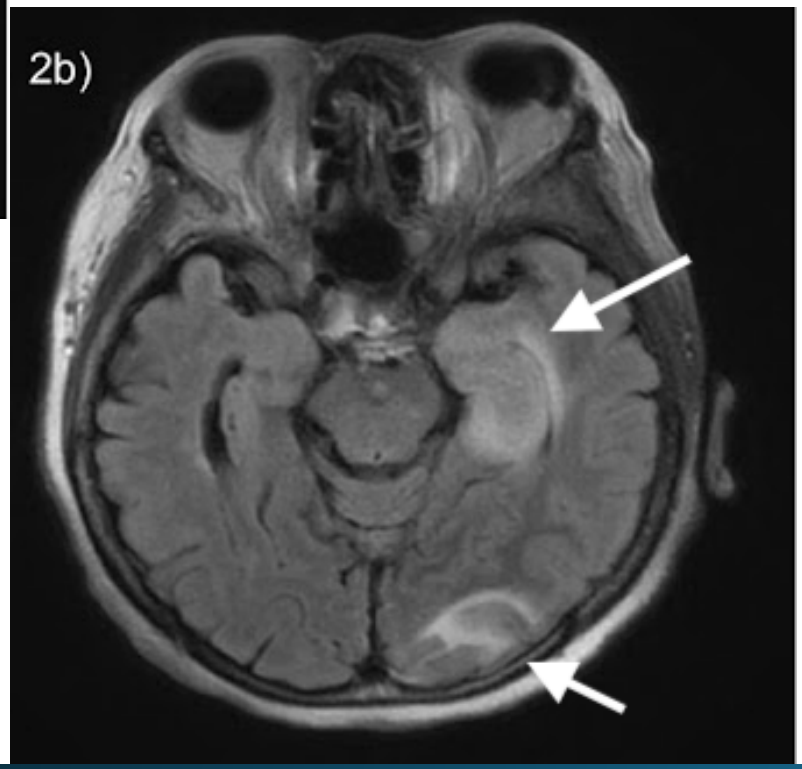

MRI Brain: Susceptibility

- Furthermore, there was extensive associated magnetic susceptibility artifact consistent with chronic hemosiderin deposition / microhemorrhage (Figure 4a-4b).

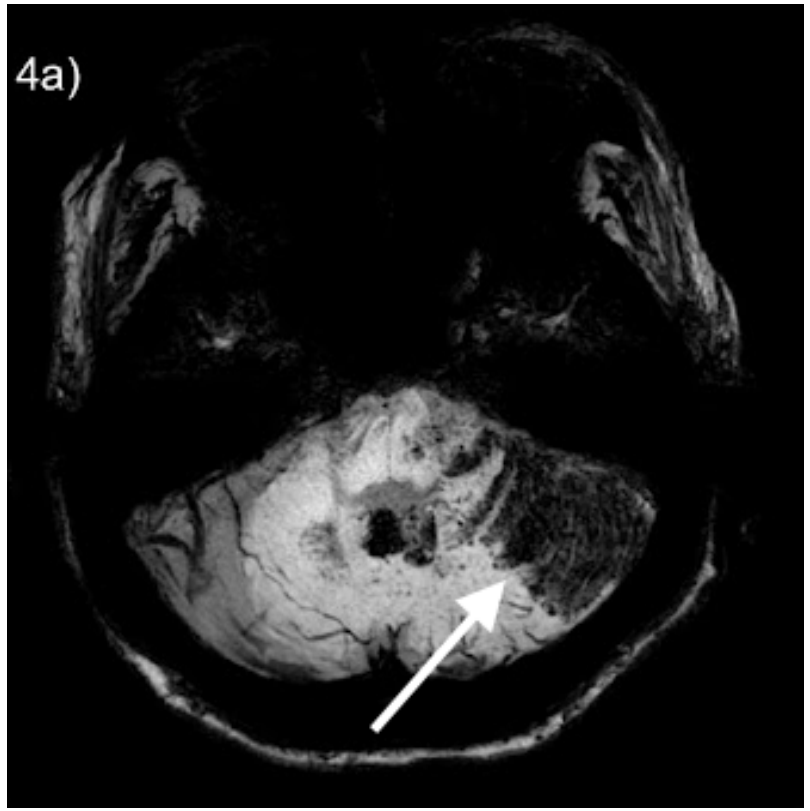

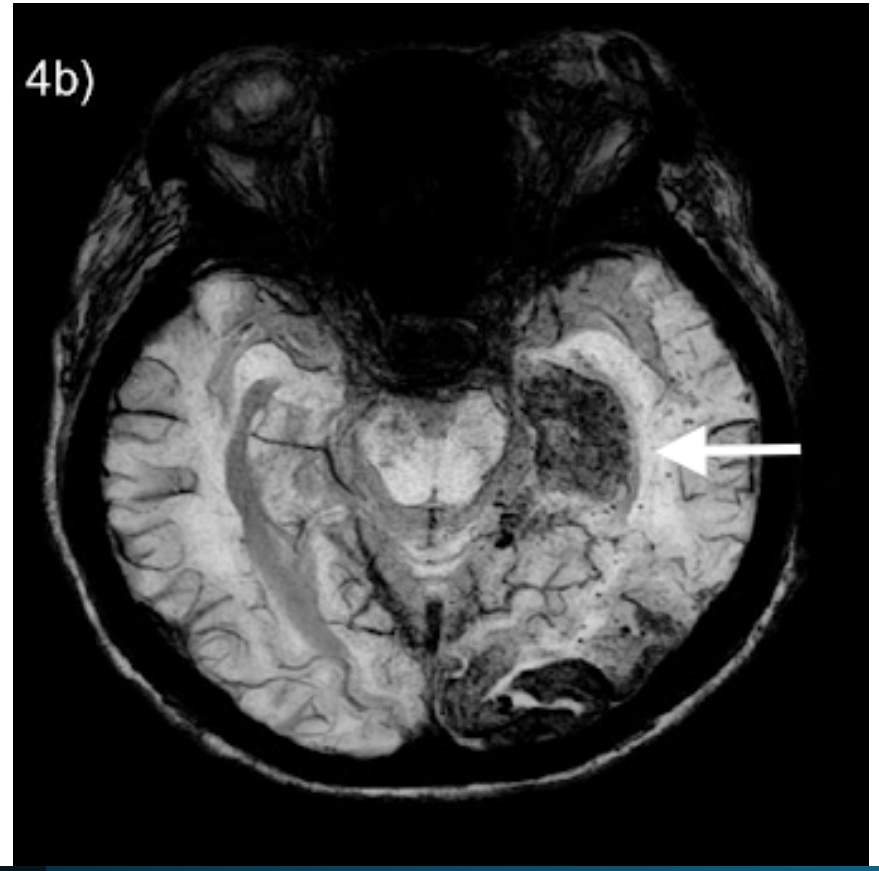

MRI Brain: Post contrast imaging

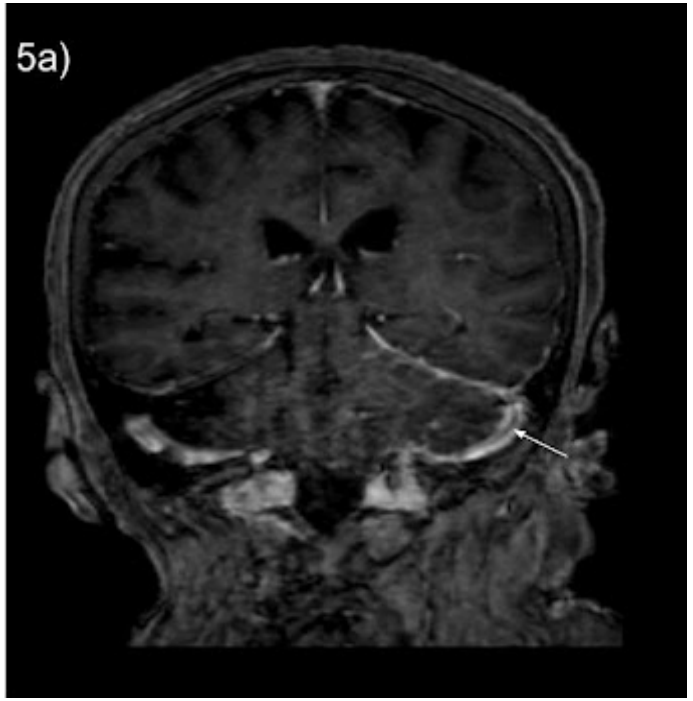

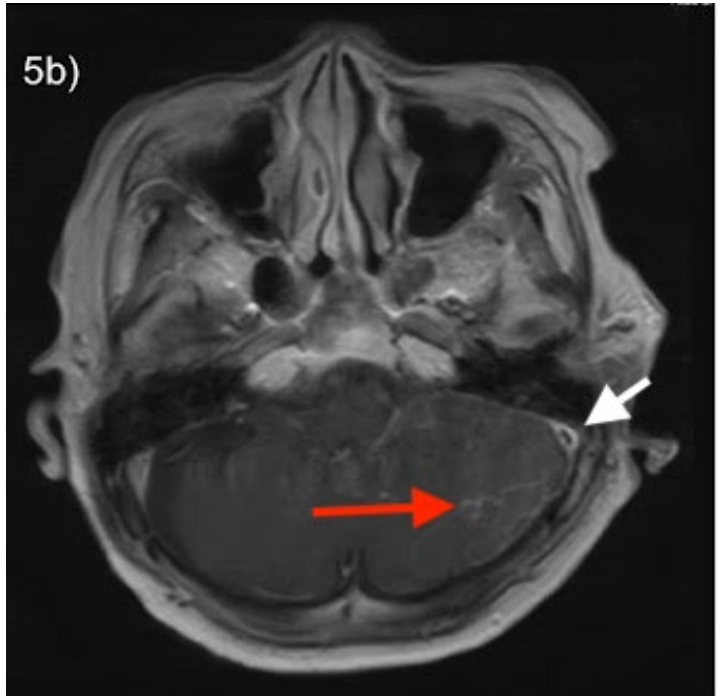

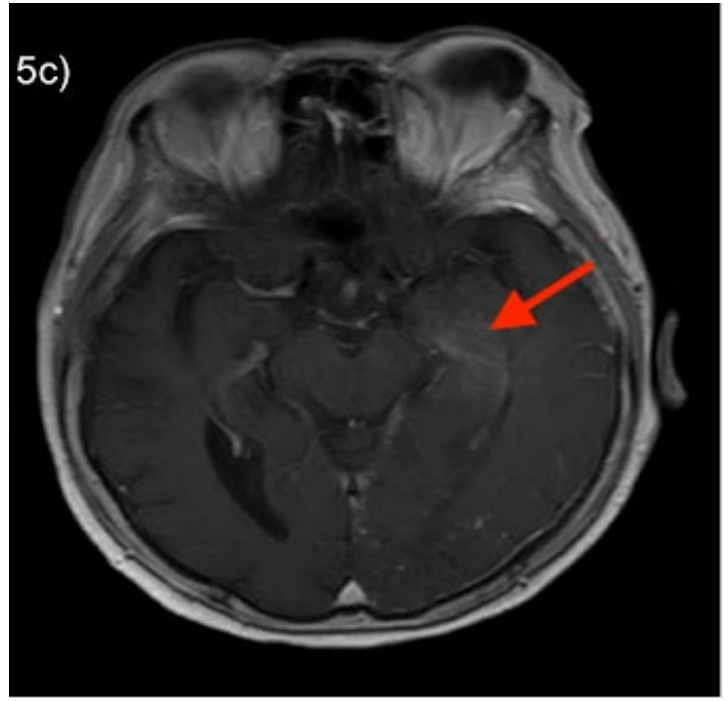

T1 Post-contrast 3D images also suggested the presence of an eccentric filling defect within the transverse-sigmoid sinus (Figures 5a-5b, white arrows). Multiple enhancing tortuous cortical venous collaterals were present in the regions of T2/FLAIR hyperintensity (Figures 5b-5c, red arrows).

MRV Head

- MRV Head showed significant asymmetric irregularity of the left transverse and sigmoid sinus, with short segment occlusion and decreased distal caliber with extensive adjacent collaterals (3D reconstruction).



Cerebral Angiogram: Pre-treatment

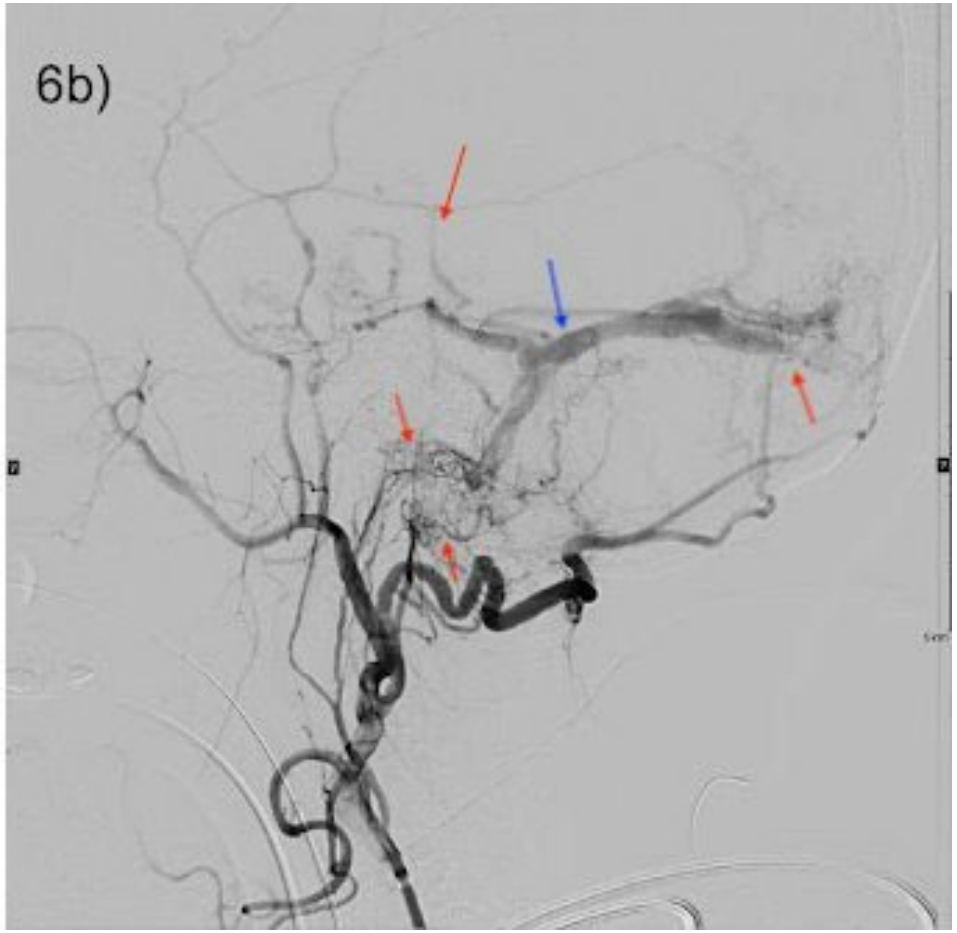

- Injection of the left ECA confirmed the presence of a left dural arteriovenous fistula.
- Branches of the occipital, ascending pharyngeal, and middle meningeal arteries (red arrows) demonstrate fistulization with a dysplastic segment of transverse/sigmoid sinus (blue arrow).
- Venous drainage of this dysplastic segment appeared to be through cortical veins of the left cerebellum and temporal lobe.
- No antegrade flow into the left IJV or retrograde flow into the contralateral transverse/sigmoid sinus was visualized.

Cerebral Angiogram: Post-treatment

- Findings overall favored to represent remote thrombosis of the left transverse and sigmoid sinuses with subsequent development of a Cognard type III dural arteriovenous fistula with resultant venous congestive edema and extensive microhemorrhage.
- Trans-arterial embolization was performed using Onyx liquid embolization. Post-treatment ECA injection demonstrated complete occlusion of the fistula without cortical venous reflux (Figure 6c).

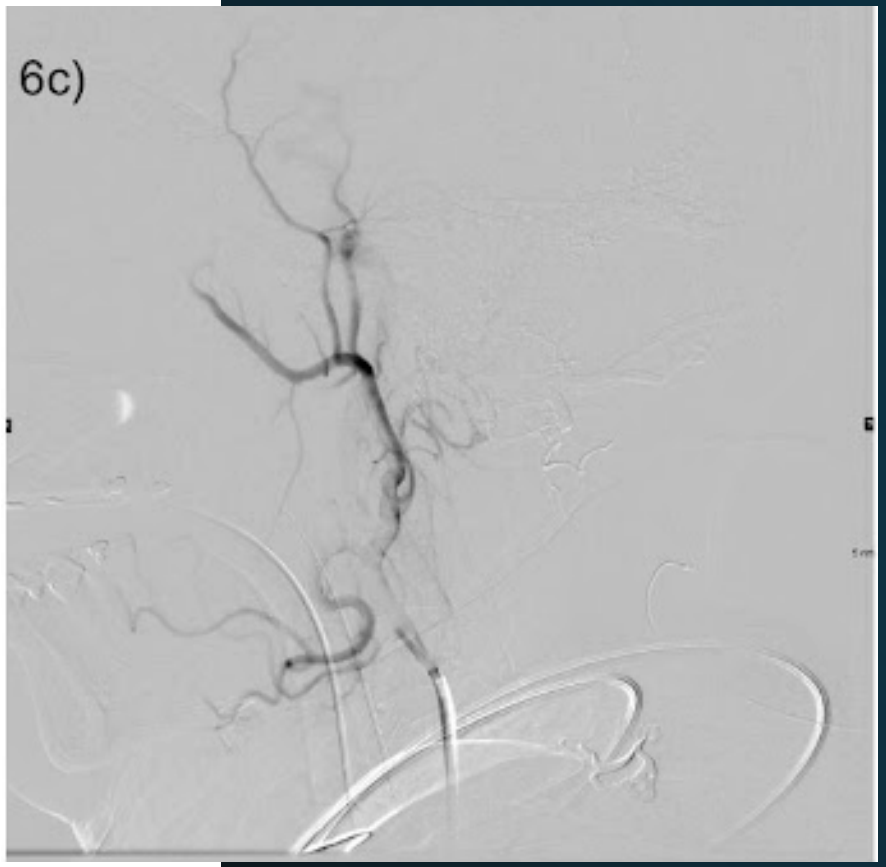

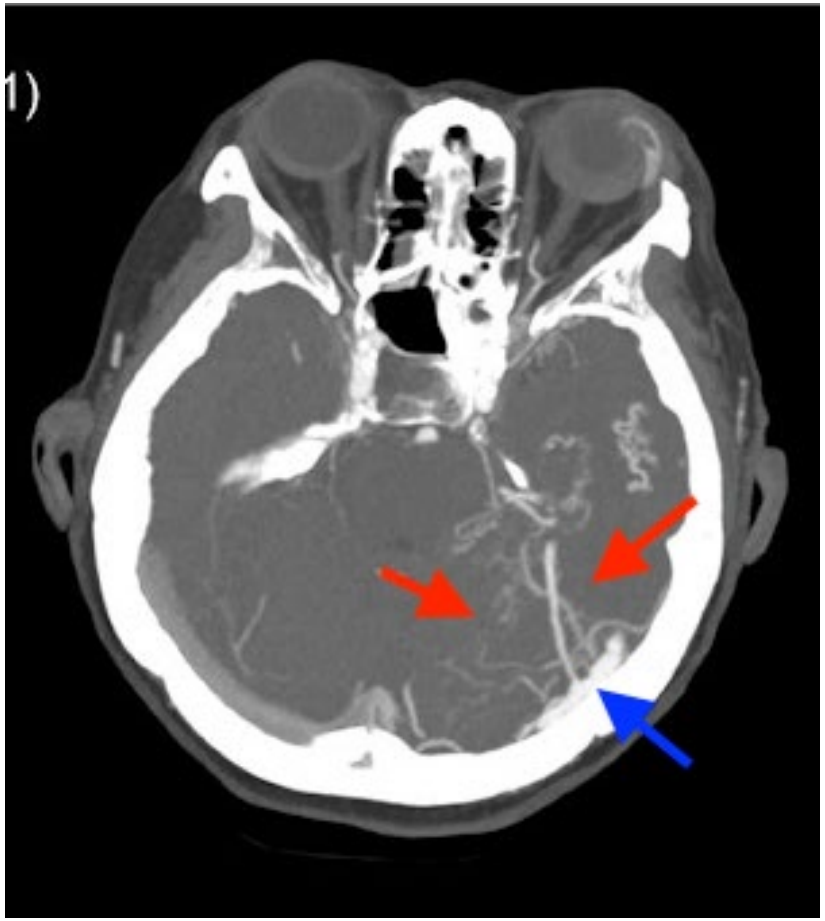

Intracranial Dural Arteriovenous Fistula

- Abnormal connection between arterial vessel and a venous structure
  - Venous sinus
  - Cortical vein
- Can be idiopathic but associated with chronic dural venous sinus thrombosis
  - Venous hypertension leading to neovascularization

Cognard Classification and Management

- Classification system for Dural AVFs, which correlate with clinical severity/risk of hemorrhage
- Based on venous drainage/reflux
- Types 1 and 2 drain within venous sinus
  - Subtypes of Type 2 depending on reflux and antegrade vs retrograde flow
- Types 1 and 2a are benign: not often treated
- Others often treated due to high risk of hemorrhage
  - Usually endovascular embolization
  - Stereotactic radiosurgery
  - Microsurgical disconnection
- Goal: Eliminate cortical veinous drainage

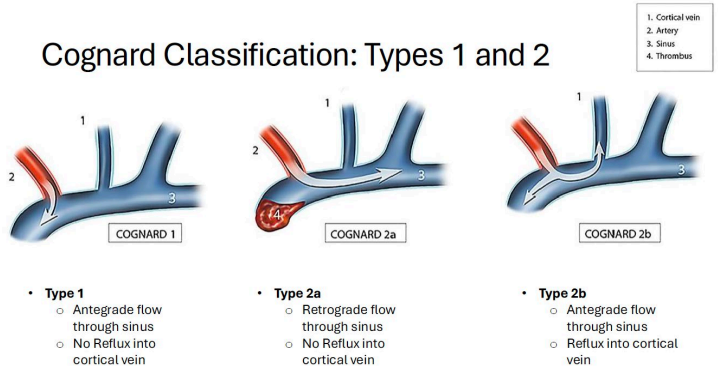

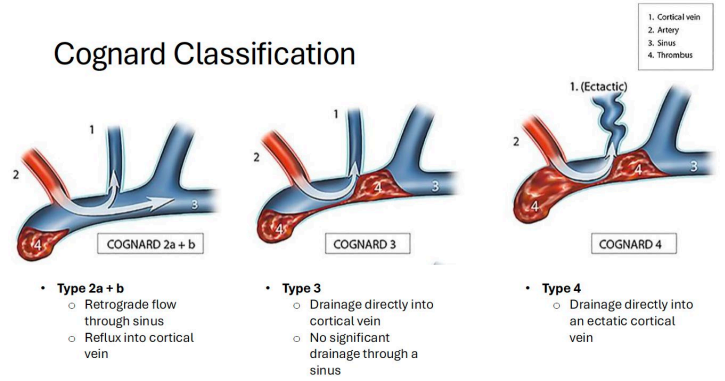

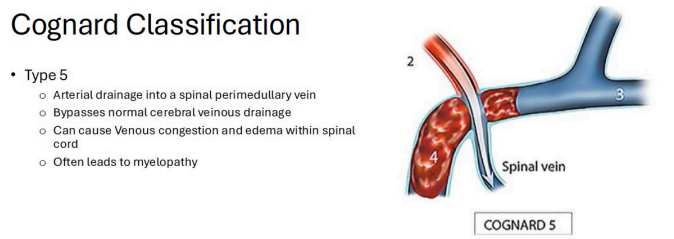

References:

- Cognard C, et al. *Cerebral dural arteriovenous fistulas: clinical and angiographic correlation with a revised classification of venous drainage.* Radiology. 1995.
- Zipfel GJ, et al. *Dural arteriovenous fistulas: a review.* Neurosurg Focus. 2009.
- Satomi J, et al. *Benign cranial dural arteriovenous fistulas: outcome of conservative management.* J Neurosurg. 2002.
- Gross BA, Du R. *The natural history of cerebral dural arteriovenous fistulae.* Neurosurgery. 2012
- Willis MD, Amato-Watkins T, Zaben M, et al. Reversible brainstem dysfunction from spinal arterio-venous fistula. Practical Neurology 2014;14:425-428.