Traumatic Left C8 Nerve Root Avulsion After Tire Blast Injury

Anastasiya Boutko, Marlee Ghobrial, Douglas Rodriguez.

USF Health Morsani College of Medicine, Tampa, FL



Clinical Presentation

- 26-year-old man after dump-truck tire blast injury.
- Unable to move bilateral upper extremities.
- Markedly decreased sensation below the elbows; patchy sensation below the shoulders.
- Initial cervical spine CT: left C7 transverse process fracture and cervical epidural hematoma.
- MRI initially deferred due to retained metallic shrapnel.

Initial Imaging



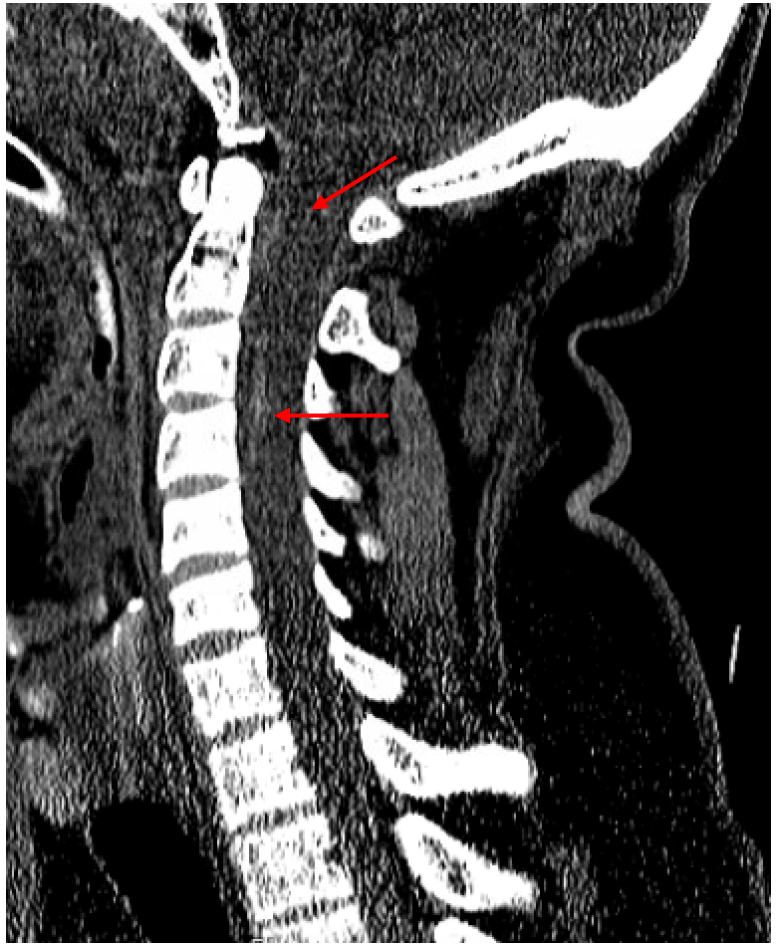

Key question: is there a localized root sleeve disruption, a surgically treatable compressive lesion, or broader plexus-level injury?

CT Cervical spine w/o contrast: left C7 transverse process fracture (→) and epidural hematoma extending from the craniocervical junction to the level of C5 (→).

CT Myelography

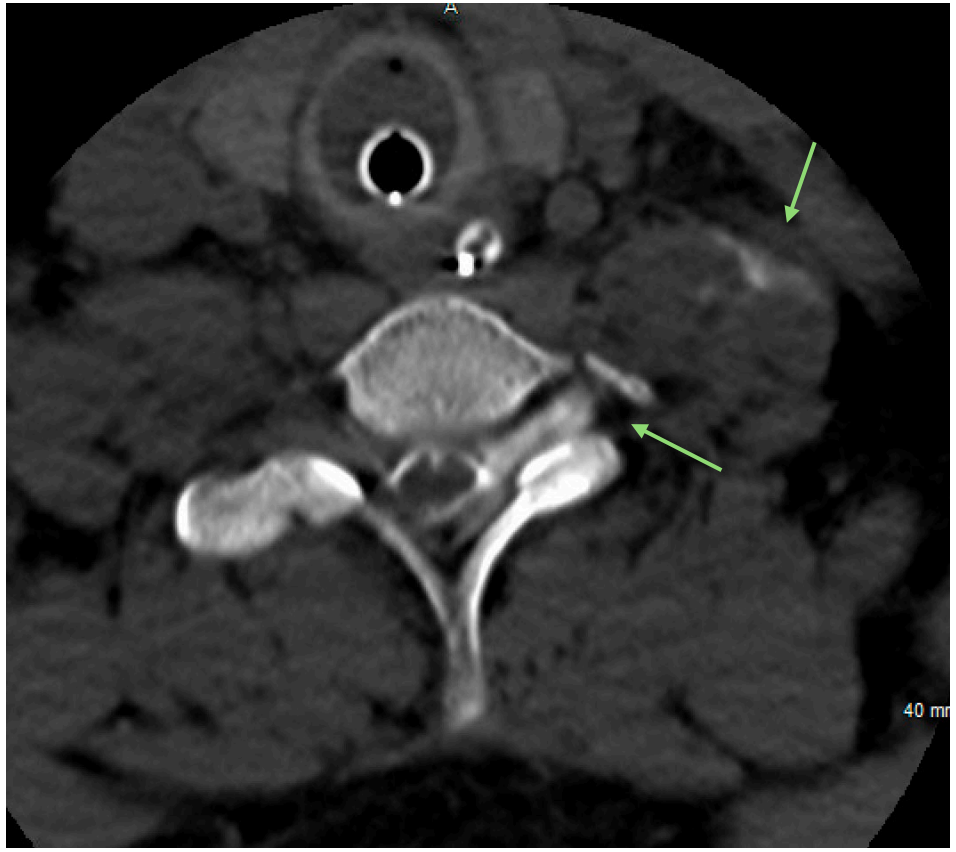

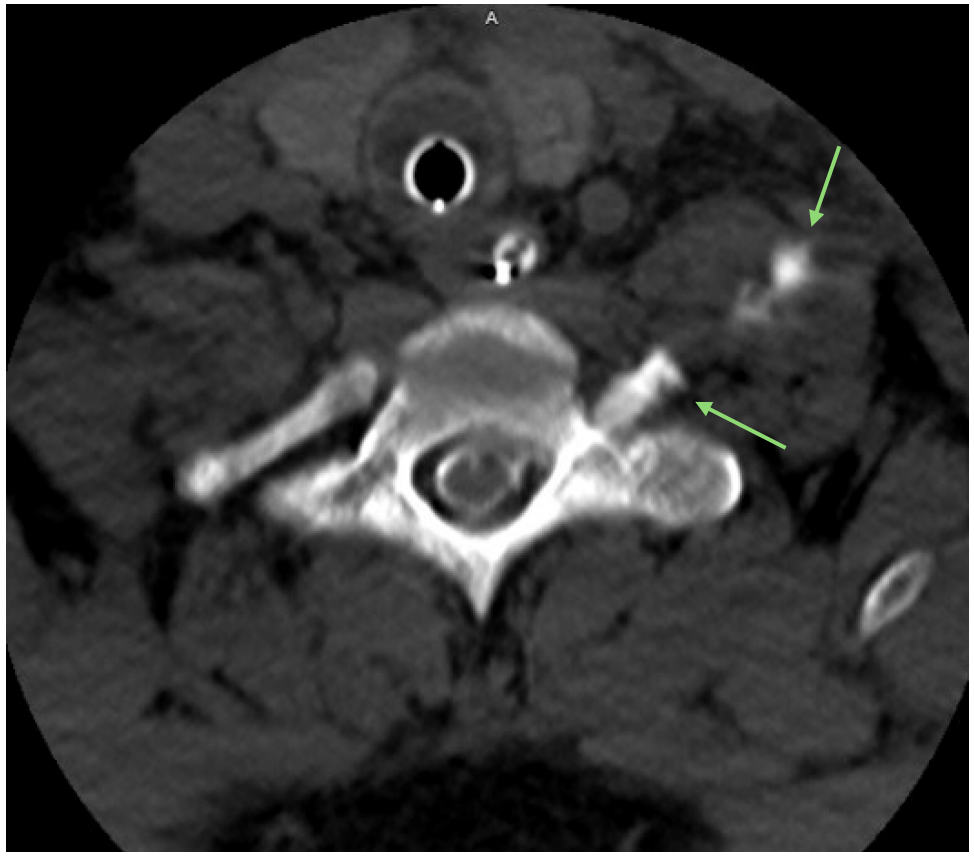

- Intrathecal contrast extravasated through the left C7–T1 neural foramen with tracking into the prevertebral musculature/adjacent soft tissues.
- Finding was compatible with traumatic disruption of the left C8 nerve root sleeve and associated CSF leak.
- No compressive lesion amenable to surgical intervention was identified.

MRI

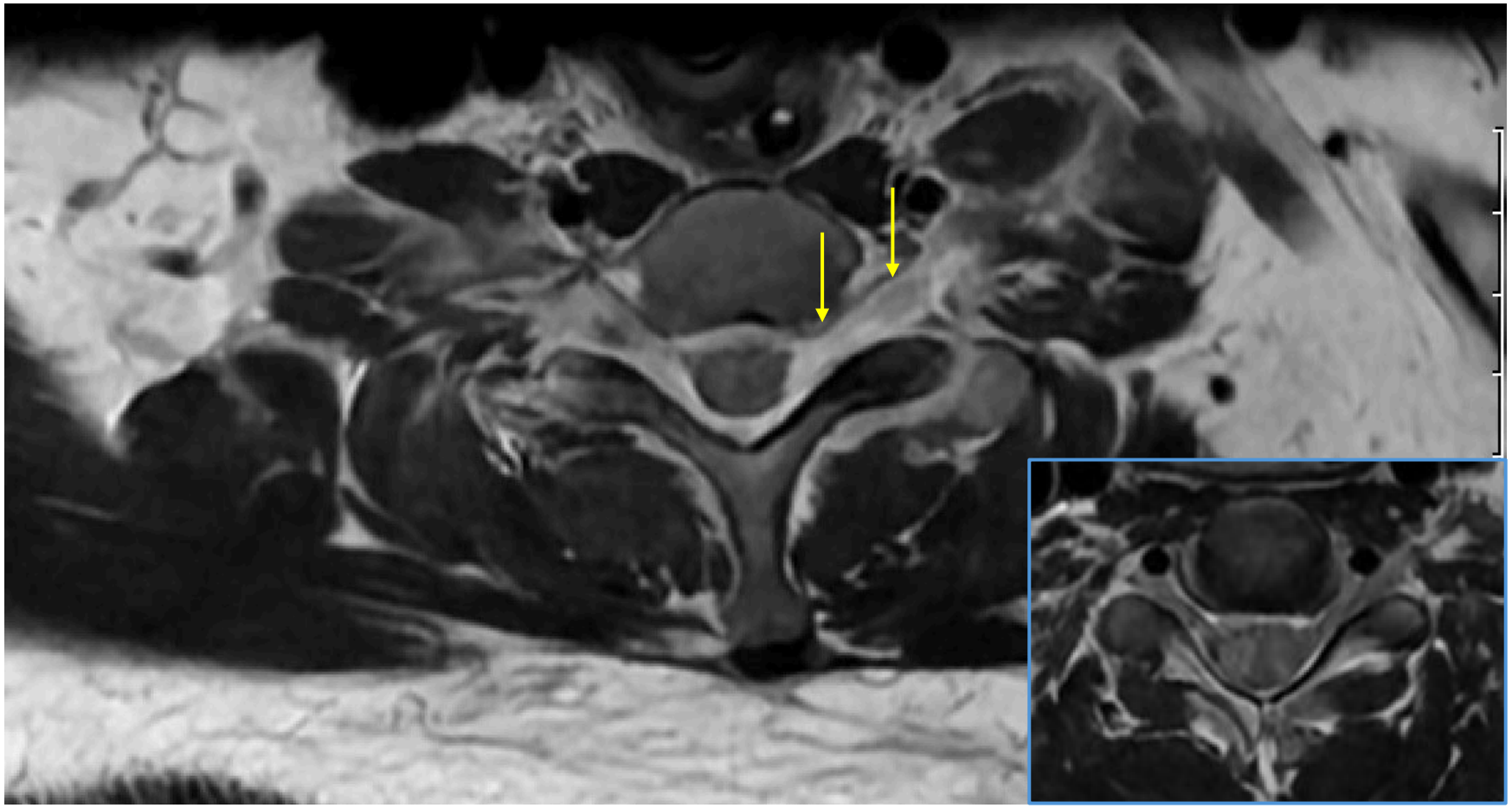

- After shrapnel removal, brachial plexus MRI demonstrated edema in the left C7–T1 neural foramen with poor visualization of the proximal C8 root.
- Cervical spine MRI showed enlargement and increased T2 signal of the left C8 nerve root ([redacted]) further supporting root avulsion.
- Lower-right image: normal-appearing adjacent level for comparison.

Imaging Discussion: CT vs MRI[1-4]

CT:

- Best for showing communication between the thecal sac and a torn root sleeve.
- Key signs: extradural contrast, pseudomeningocele, absent/nonvisualized rootlets.
- Especially useful when MRI is contraindicated, limited, or delayed.

MRI:

- Best for soft-tissue characterization of root, foramen, cord, muscles, and plexus.
- Key signs: foraminal edema, root T2 hyperintensity/enlargement, nonvisualized root, denervation changes.
- Complements CTM and EMG; it does not replace clinical correlation.

Management and outcome

Management:

- No compressive lesion amenable to surgical intervention.
- Neurosurgery recommended nonoperative management.
- Treatment focused on pain control, rehabilitation, and planned EMG/NCS follow-up.

Outcome:

- Discharged to inpatient rehabilitation.
- EMG: very severe bilateral brachial plexopathies involving upper, middle, and lower trunks.
- Persistent bilateral upper-extremity flaccid paralysis and neuropathic pain.
- Later readmission for worsening neck/back pain and left-leg symptoms.
- Follow-up imaging showed no new acute cervical injury; conservative management continued.

Take Home Points

- CT myelography can directly localize traumatic root sleeve disruption/CSF leak when MRI is initially limited or contraindicated.
- Key CTM clue: intrathecal contrast extending through a neural foramen into adjacent soft tissues.
- MRI is complementary for characterizing the injured root, neural foramen, cord, and brachial plexus.
- In complex trauma, focal root avulsion may coexist with severe plexopathy—correlate imaging with EMG and neurologic exam.

Thank you!

References:

1. Carvalho GA, Nikkhah G, Matthies C, Penkert G, Samii M. Diagnosis of root avulsions in traumatic brachial plexus injuries: value of computerized tomography myelography and magnetic resonance imaging. J Neurosurg. 1997;86(1):69–76.
2. Doi K, Otsuka K, Okamoto Y, Fujii H, Hattori Y, Baliarsing AS. Cervical nerve root avulsion in brachial plexus injuries: magnetic resonance imaging classification and comparison with myelography and computerized tomography myelography. J Neurosurg. 2002;96(3 Suppl):277–284.
3. Yoshikawa T, Hayashi N, Yamamoto S, et al. Brachial plexus injury: clinical manifestations, conventional imaging findings, and the latest imaging techniques. Radiographics. 2006;26 Suppl 1:S133–S143.
4. Wade RG, Takwoingi Y, Wormald JCR, et al. MRI for detecting root avulsions in traumatic adult brachial plexus injuries: systematic review and meta-analysis of diagnostic accuracy. Radiology. 2019;293(1):125–133.