

Beyond the Classic Imaging Triad: Expanded Neuroimaging Findings in *CCND2*-Associated MPPH Syndrome

Aeva Jazic BS, Asha Sarma MD, and Alexandra Foust DO

Monroe Carell Jr.
Children's Hospital
at Vanderbilt

Disclosures

- None

Clinical Presentation

- Term female with prenatally diagnosed ventriculomegaly, right hydroureter, and enlarged echogenic kidneys
- At birth, macrocephaly (HC 97th %ile), left foot polydactyly, and anteriorly displaced anus, suspicious for anorectal malformation



Imaging Discussion

Skeletal Survey:

- Post-axial sixth digit
- Bilateral cervical ribs
- T5 butterfly vertebra
- Sacral dysgenesis

Remaining survey negative



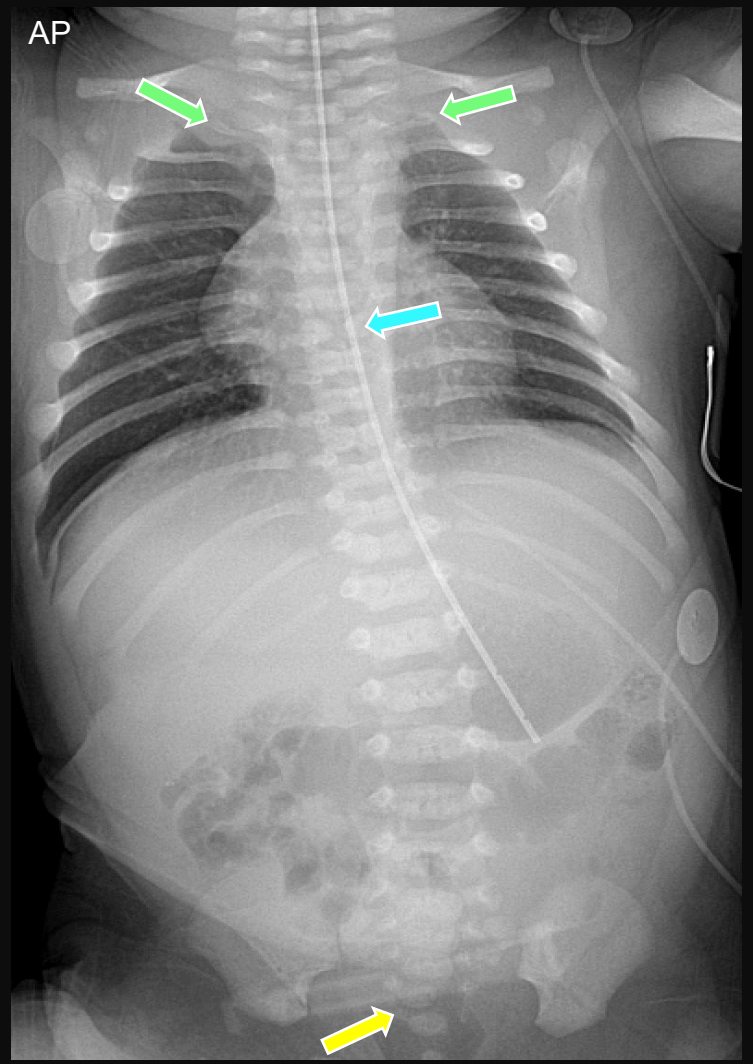

Imaging Discussion

Brain MRI (malformative):

- Extensive frontoparietotemporal & perisylvian polymicrogyria
- Ventriculomegaly
- Dysmorphic corpus callosum
- Thickened tectum
- Pons hypoplasia

Birth related/ischemic findings:

- Left caudothalamic groove grade I germinal matrix hemorrhage
- White matter ischemic injury
- Right temporal horn subependymal hemorrhage

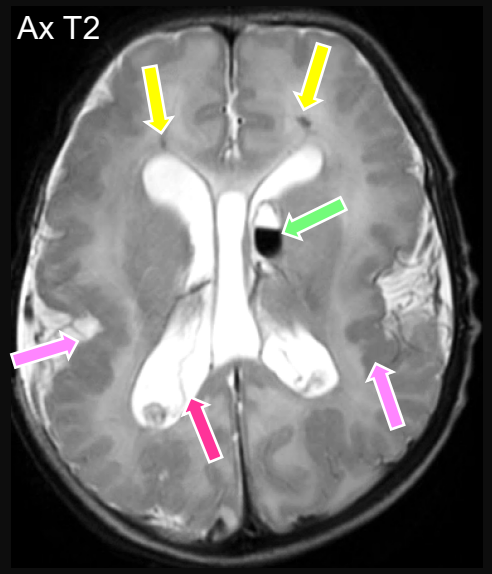

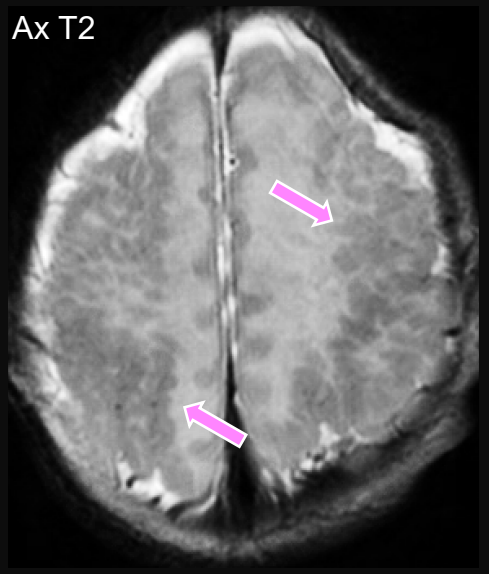

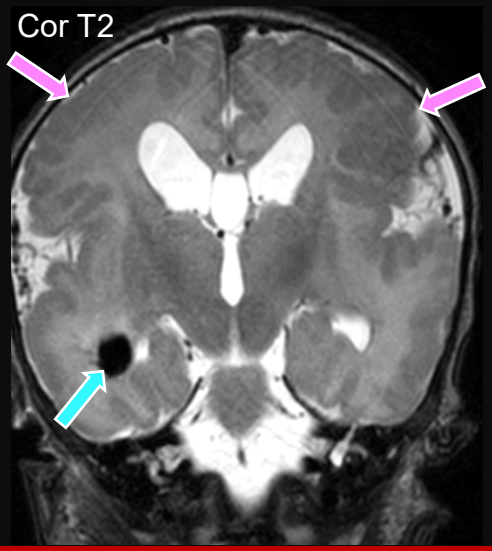

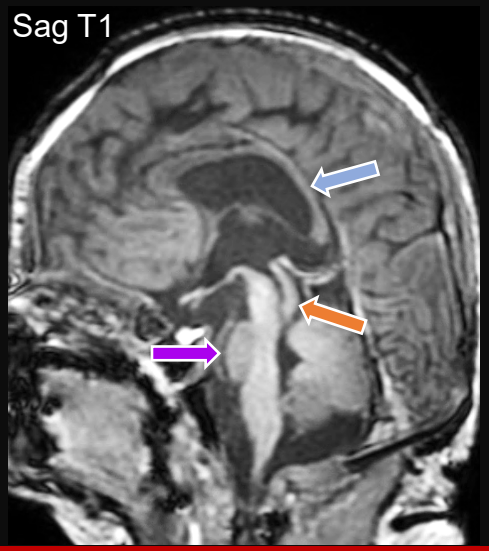

Imaging Discussion

- Classic tetrad for megalencephaly-polymicrogyria-polydactyly-hydrocephalus (MPPH) syndrome:
  1. Megalencephaly
  2. Bilateral perisylvian polymicrogyria
  3. Post-axial polydactyly
  4. Ventriculomegaly/hydrocephalus
- Typical feature: Dysmorphic corpus callosum (usually thickened)
- Megalencephaly-capillary malformation (MCAP) syndrome has similar features + vascular malformations & segmental body overgrowth

Imaging Discussion

Atypical Brain Features in Current Case

- Tectal dysmorphism
- Pontine hypoplasia
- Grade I germinal matrix hemorrhage, subependymal hemorrhage, and white matter ischemic injury (likely unrelated to MPPH)

Additional Features

- Butterfly vertebra
- Cervical ribs
- Cystic dysplastic kidney (not pictured)
- Anorectal malformation (not pictured)

Second Diagnosis?

VACTERL?
CAKUT?

Management

- Multiple antiseizure medications for refractory epilepsy
- Tube feed dependent given oropharyngeal dysphagia (thought to be related to perisylvian polymicrogyria)
- Surgical correction of anorectal malformation
- Antibiotic prophylaxis for vesicoureteral reflux (resolved by 18 months of age)

Outcome

- Genetic testing found a likely pathogenic variant in *CCND2,* confirming MPPH
- Patient has developmental delay, cortical vision impairment, chronic constipation, and a single functioning left kidney
- Follow-up brain MRI at 1 year:
  - Progressive cerebral white matter volume loss
  - Increased supratentorial ventricle size
  - Cerebellar parenchymal dysplasia apparent with progression of myelination

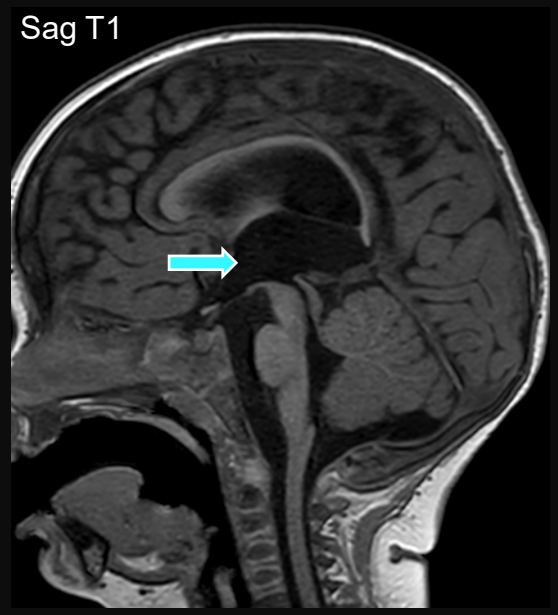

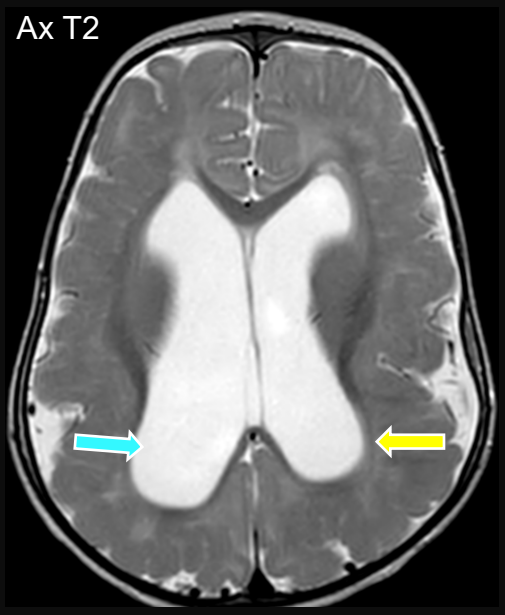

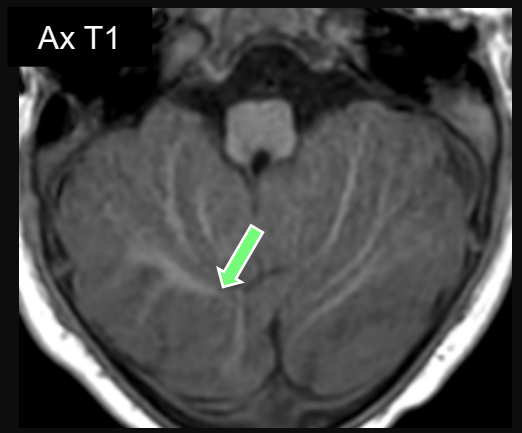

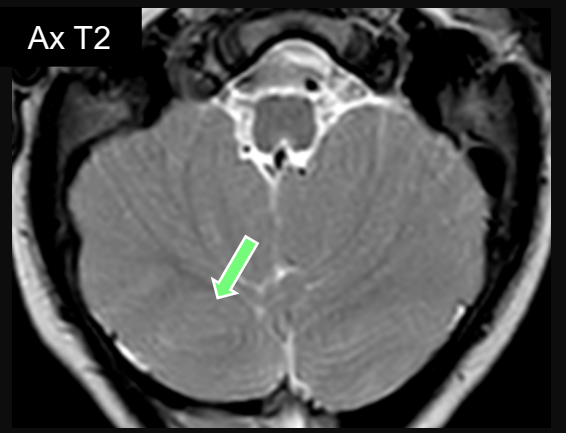

Take Home Points

- MPPH syndrome is a rare disorder caused by pathogenic variants in the genes *PIK3R2*, *AKT3*, and *CCND2*
- Key diagnostic features include macrocephaly or megalencephaly, perisylvian polymicrogyria, hydrocephalus, and post-axial polydactyly
- Recognition of this neuroimaging pattern can facilitate targeted genetic testing and earlier diagnosis of MPPH syndrome

Thank you!

Questions?

Contact: aeva.jazic@vanderbilt.edu

Monroe Carell Jr.
Children's Hospital
at Vanderbilt

References

1. Mirzaa G, Dodge NN, Glass I, et al. Megalencephaly and perisylvian polymicrogyria with postaxial polydactyly and hydrocephalus: a rare brain malformation syndrome associated with mental retardation and seizures. *Neuropediatrics*. 2004;35(6):353-359. doi:10.1055/s-2004-830497
2. Libzon S, Hausman-Kedem M, Waiserberg N, Ben Sira L. Fetal magnetic resonance imaging features of syndromic megalencephaly: a systematic review of imaging-genotype associations. *Pediatr Radiol*. Published online August 18, 2026. doi:10.1007/s00247-026-06747-3
3. Cappuccio G, Ugga L, Parrini E, D'Amico A, Brunetti-Pierri N. Severe presentation and complex brain malformations in an individual carrying a *CCND2* variant. *Mol Genet Genomic Med*. 2019;7(6):e708. doi:10.1002/mgg3.708
4. Mirzaa G, Parry DA, Fry AE, et al. De novo *CCND2* mutations leading to stabilization of cyclin D2 cause megalencephaly-polymicrogyria-polydactyly-hydrocephalus syndrome. *Nat Genet*. 2014;46(5):510-515. doi:10.1038/ng.2948
5. Zhao MF, Zhang SL, Xiang Y, et al. A *de novo* mutation (p.Gln277X) of cyclin D2 is responsible for a child with megalencephaly-polymicrogyria-polydactyly-hydrocephalus syndrome. *DNA Cell Biol*. 2024;43(7):325-330. doi:10.1089/dna.2023.0391
6. Mirzaa GM, Conti V, Timms AE, et al. Characterisation of mutations of the phosphoinositide-3-kinase regulatory subunit, *PIK3R2*, in perisylvian polymicrogyria: a next-generation sequencing study. *Lancet Neurol*. 2015;14(12):1182-1195. doi:10.1016/S1474-4422(15)00278-1
7. Mok KM, Carpenter JL, Herrada P, Greene C, Yazbek S, Erdemir G. Rare *CCND2* (p.Thr280Ile) variant associated with infantile spasms in a patient with megalencephaly-polymicrogyria-polydactyly-hydrocephalus syndrome. *Pediatr Neurol*. 2024;161:185-187. doi:10.1016/j.pediatrneurol.2024.09.016
8. Mirzaa GM. MPPH syndrome. In: Adam MP, Bick S, Mirzaa GM, et al, eds. *GeneReviews®*. University of Washington, Seattle; 1993-2026. Updated July 28, 2022. Accessed September 13, 2026.
9. Pirozzi F, Lee B, Horsley N, et al. Proximal variants in *CCND2* associated with microcephaly, short stature, and developmental delay: a case series and review of inverse brain growth phenotypes. *Am J Med Genet A*. 2021;185(9):2719-2738. doi:10.1002/ajmg.a.62362
10. Mirzaa GM, Conway RL, Gripp KW, et al. Megalencephaly-capillary malformation (MCAP) and megalencephaly-polydactyly-polymicrogyria-hydrocephalus (MPPH) syndromes: two closely related disorders of brain overgrowth and abnormal brain and body morphogenesis. *Am J Med Genet A*. 2012;158A(2):269-291. doi:10.1002/ajmg.a.34402