A NEURORADIOLOGY CASE EXHIBIT

Tumor or Aneurysm?

Five illustrative cases

Abhishek Kattel, MS3

Kevin Hiatt, MD

Wake Forest University
School of Medicine

CASE 1

A fall, and a lesion right next to the left PICA

Tumor vs Aneurysm · Five-case neuroradiology exhibit

CASE 1 · THE CASE

A fall, and a lesion right next to the left PICA

- **65-year-old man** w/ PMH of HTN and bipolar disorder
- **New gait instability** → fall down the stairs
- Exam: truncal ataxia, L>R limb dysmetria
- Cranial nerves, strength, sensation intact
- CTA: Ovoid lesion with arterial contrast density lesion along left PICA

FIRST IMAGING — CTA

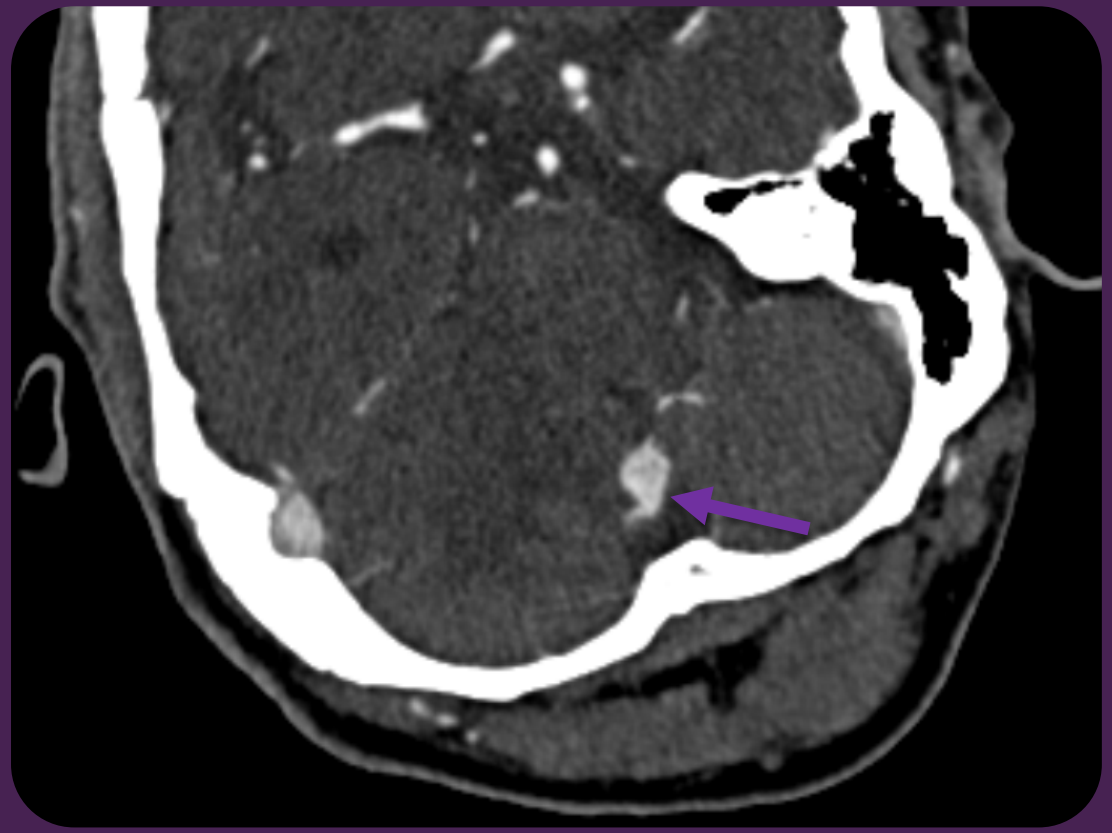

Midline infravermian lesion adjacent to left PICA

Tumor or **aneurysm**?

CASE 1 · THE CASE

A fall, and a lesion right next to the left PICA

- **65-year-old man** w/ PMH of HTN and bipolar disorder
- **New gait instability** → fall down the stairs
- Exam: truncal ataxia, L>R limb dysmetria
- Cranial nerves, strength, sensation intact
- CT: Edema in the right cerebellar hemisphere

FIRST IMAGING — CT

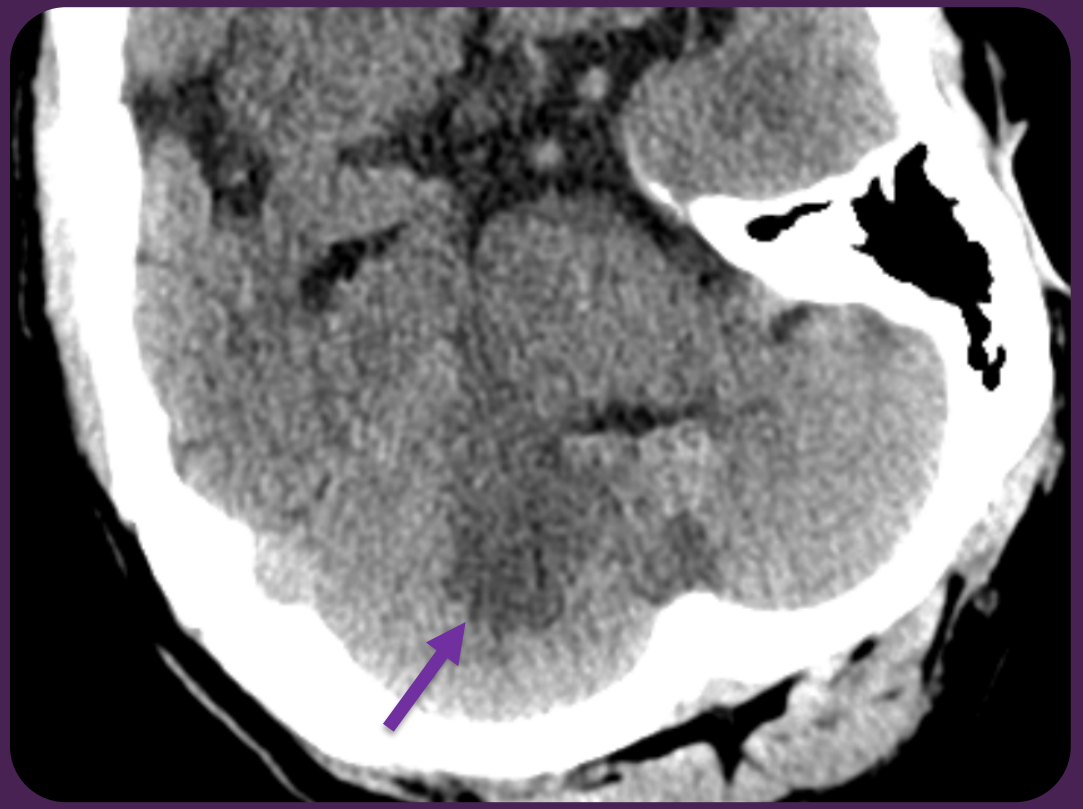

Adjacent right cerebellar edema

Tumor or **aneurysm**?

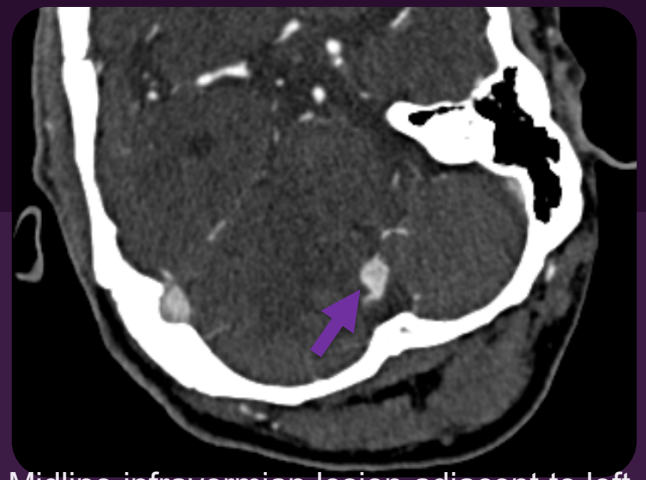

Midline infravermian lesion adjacent to left PICA

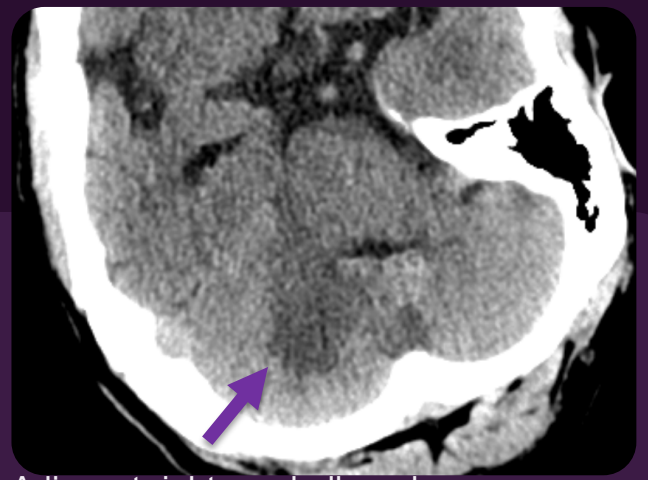

Adjacent right cerebellar edema

STROKE SERVICE

Working impression:

Based off the CTA -> Initial concern was for a left PICA aneurysm, though the finding of right cerebellar edema was unusual for aneurysm, so MRI was obtained

Tumor or **aneurysm**?

CASE 1 · IMAGING

MRI: an enhancing nodule and adjacent edema

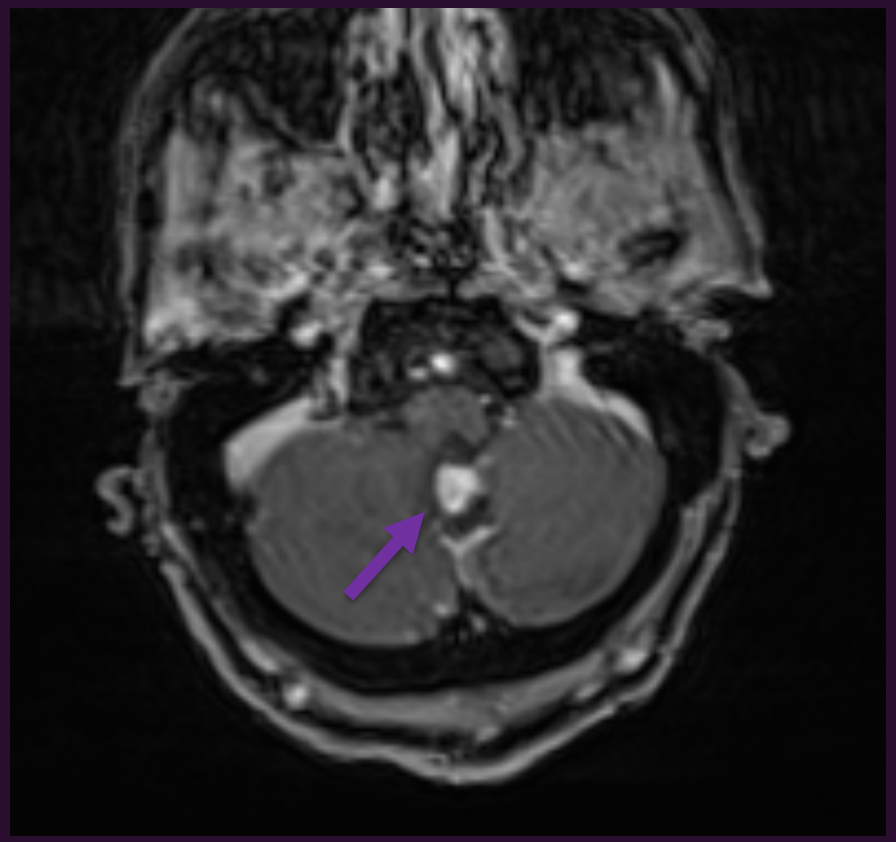

Postcontrast T1 · 12 mm avidly enhancing vermian nodule

Enhancing nodule + edema → favors neoplasm (hemangioblastoma)

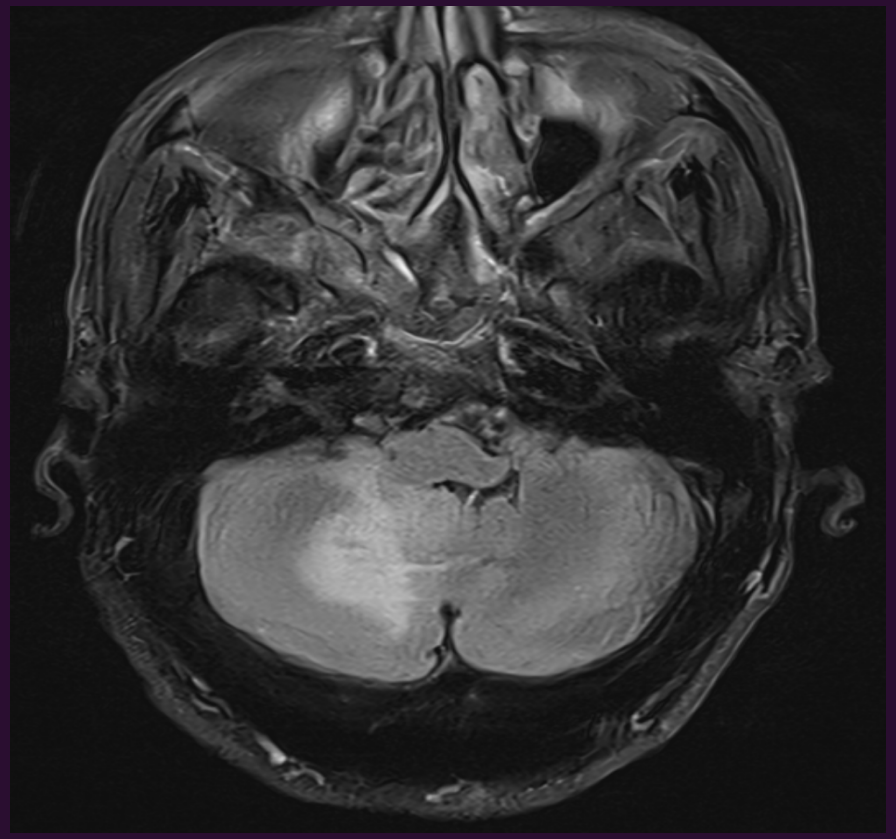

FLAIR · right cerebellar vasogenic edema

CASE 1 · THE WORKUP

From anatomy to physiology



MRI

Enhancing vermian nodule + edema

favors tumor

›

DSA

Capillary “tumor blush” fed by PICA

Does not look like aneurysm

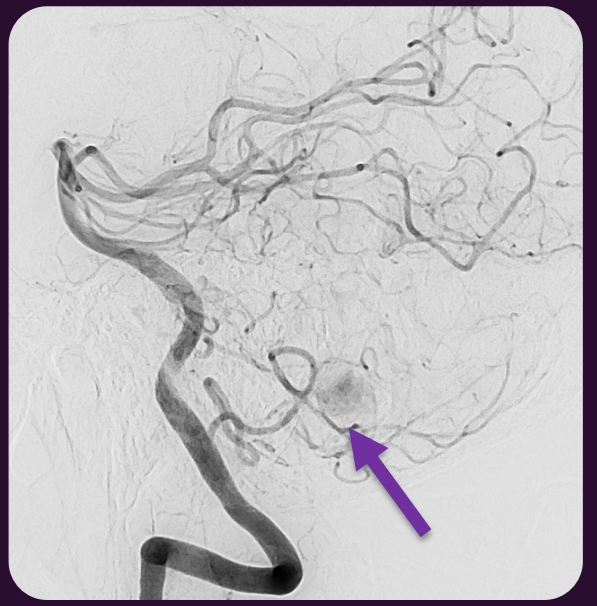

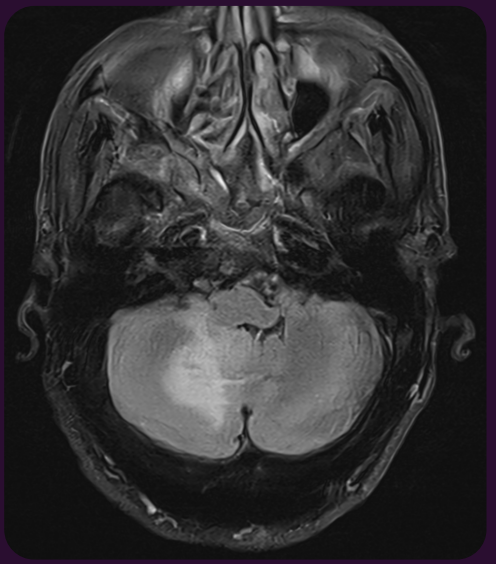

Diagnosis: **HEMANGIOBLASTOMA** → made on imaging + angiography, no biopsy

How we excluded aneurysm: an aneurysm fills like its parent artery and has a neck → this lesion had neither

CASE 1 · MANAGEMENT

Treat the edema, hunt for VHL, then radiosurgery

- **Dexamethasone** → edema down, ataxia improved
- **Hemangioblastoma** → **work up VHL**
  eye exam (normal), genetics referral, known renal lesion
- Options: observe vs Gamma Knife vs resection
- **Chose Gamma Knife radiosurgery** (18 Gy)
- Follow-up MRI: lesion stable

TEACHING POINT

A vascular posterior-fossa lesion abutting an artery is a classic tumor-vs-aneurysm dilemma.

Enhancement pattern + DSA differentiate it.

Be suspicious of the “aneurysm” with adjacent parenchymal edema.

“Hemangioblastoma” → screen for VHL

CASE 2

A first-ever headache behind the left eye

Tumor vs Aneurysm · Five-case neuroradiology exhibit

CASE 2 · THE CASE

A first-ever headache behind the left eye

- **71-year-old woman w/ PMH of** HTN, 40-yr smoking Hx & CAD
- **Sudden severe left-sided headache**, radiating to the jaw
- Worst headache of her life → woke her at 5 AM
- Exam intact: no vision change, no nerve palsy
- CT: hyperattenuating left cavernous-sinus mass (~3 cm)

FIRST IMAGING — NON-CONTRAST CT



Dense left cavernous-sinus mass, new from 10 years earlier

Tumor or **aneurysm**?

CASE 2 · THE CASE

A first-ever headache behind the left eye

- **71-year-old woman w/ PMH of** HTN, 40-yr smoking Hx & CAD
- **Sudden severe left-sided headache**, radiating to the jaw
- Worst headache of her life → woke her at 5 AM
- Exam intact: no vision change, no nerve palsy
- MRI: markedly T2 hypointense, enhancing nodule anteriorly contiguous with ICA, nonenhancement posteriorly, no pulsation artifact

SECOND IMAGING — MRI

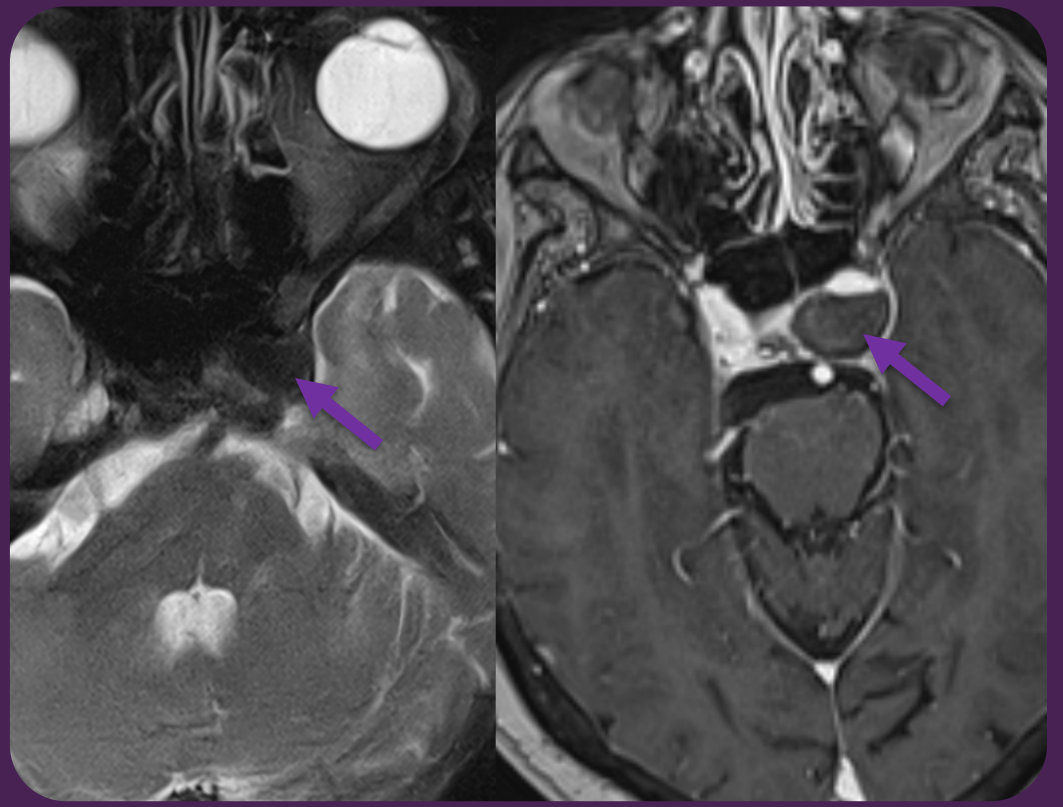

Left – T2; Right – VIBE postcontrast

Tumor or **aneurysm**?

CASE 2 · FIRST IMPRESSIONS

First read: a cavernous meningioma

FIRST LOOK · CT

Read as a

cavernous meningioma

a benign tumor → “get an outpatient MRI”

SECOND LOOK · MRI

T2-dark + susceptibility = blood clot

→ maybe a **thrombosed aneurysm**

The trap: a partially thrombosed aneurysm can mimic a solid cavernous tumor.

CASE 2 · THE WORKUP

From anatomy to physiology

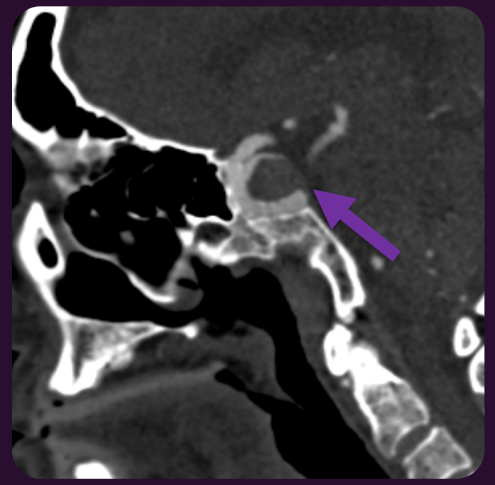

MRI — T2-dark + susceptibility = layered thrombus
not a solid tumor

CTA — Enhancement continuous with the carotid lumen
shares the artery

DSA — Dome fills straight from the ICA
fills off the carotid

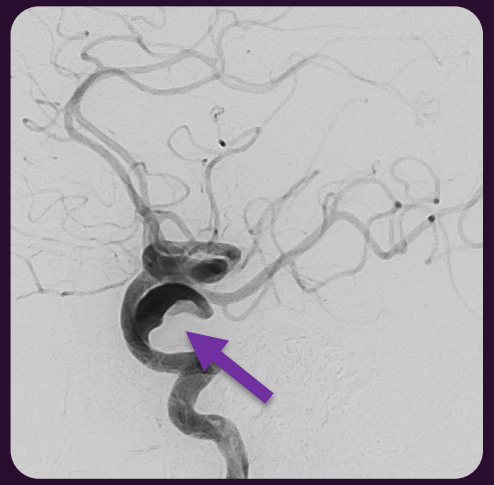

Diagnosis: **Partially thrombosed cavernous ICA aneurysm** (~1.8 cm)

How we excluded tumor: a meningioma is solid and never shares a lumen with the carotid → this lesion filled directly from it.

CASE 2 · MANAGEMENT

A flow-diverter, not a scalpel

- **Pre-treat with dual antiplatelets** (aspirin + ticagrelor)
- **Pipeline flow-diverting stent** across the aneurysm neck

  deployed endovascularly, via the wrist (radial)
- Balloon angioplasty to seat the stent

  → contrast stagnation in the dome (it's working)
- Neuro-ICU monitoring → home, NSGY follow-up

TEACHING POINT

A partially thrombosed cavernous aneurysm is a classic meningioma mimic.

Layered-thrombus + a lumen continuous with the carotid flip the diagnosis.

Think about aneurysm when a lesion is very T2 hypointense

Treatment is **endovascular flow diversion**

CASE 3

Leg pain, then a cord under pressure

Tumor vs Aneurysm · Five-case neurosurgery exhibit

CASE 3 · THE CASE

Leg pain, then a cord under pressure

- **73-year-old woman w/ PMH of** HTN, anxiety and osteoarthritis
- **Migrating paresthesias** → hands, then trunk, then legs
- Then severe right-leg pain and new weakness
- Admitted for radiculopathy; symptoms briefly resolved
- Days later: **can't stand, brisk reflexes, upgoing toes**
- MRI: Spinal canal hemorrhage, associated small enhancing nodule along the cord surface

KEY IMAGING — MRI THORACIC SPINE



Left – T2; Right – T1 postcontrast fat sat

Tumor or **aneurysm**?

CASE 3 · FIRST IMPRESSIONS

An enhancing mass inside a bleed

THORACIC MRI

Enhancing nodule in a cord-compressing bleed

→ hemorrhagic **tumor vs aneurysm**

The trap: an enhancing nodule in a spinal hematoma can look just like a hemorrhagic tumor (e.g. hemangioblastoma).

CASE 3 · THE WORKUP

From anatomy to physiology



MRI

Enhancing nodule within canal hemorrhage + cord compression

tumor vs vascular

›

DSA

Fusiform aneurysm off a left intercostal artery, T3-4

diagnostic of aneurysm



Diagnosis: **Ruptured spinal segmental-artery aneurysm** (T3-4, ~6.5 mm)

How we excluded tumor: the enhancing nodule was the aneurysm itself, filling off the intercostal artery → no tumor tissue.

CASE 3 · MANAGEMENT

A scalpel, not a coil

- **Endovascular attempt first** → aneurysm not reachable by catheter
- **T1-T5 laminectomy** to evacuate the cord-compressing clot

  with microsurgical clot removal + aneurysm exploration
- Returned to her neurologic baseline after surgery

  → post-op ileus and transient AKI, both resolved
- Incidental T6-7 aneurysm → surveillance CTA in 3 months

TEACHING POINT

An enhancing nodule inside a spinal hematoma → get catheter angiography before calling it a tumor.

Treatment is **open evacuation** when the aneurysm can't be reached endovascularly.

CASE 4

Found down, confused — a calcified mass

Tumor vs Aneurysm · Five-case neuroradiology exhibit

CASE 4 · THE CASE

Found down, confused → a calcified mass

- **67-year-old woman w/ PMH of** 20.5 pack/yr smoker, on daily aspirin
- **Found down at home** → brought in confused (AMS)
- Exam: disoriented, but no focal deficit
- No headache, no thunderclap, no SAH
- CT: peripherally calcified 5 cm central mass + hydrocephalus

FIRST IMAGING — NON-CONTRAST CT



Peripherally calcified midline mass with hydrocephalus

Tumor or **aneurysm**?

CASE 4 · THE CASE

Found down, confused → a calcified mass

- **67-year-old woman w/ PMH of** 20.5 pack/yr smoker, on daily aspirin
- **Found down at home** → brought in confused (AMS)
- Exam: disoriented, but no focal deficit
- No headache, no thunderclap, no SAH
- MRI: markedly hypointense internal T2 signal

SECOND IMAGING — MRI

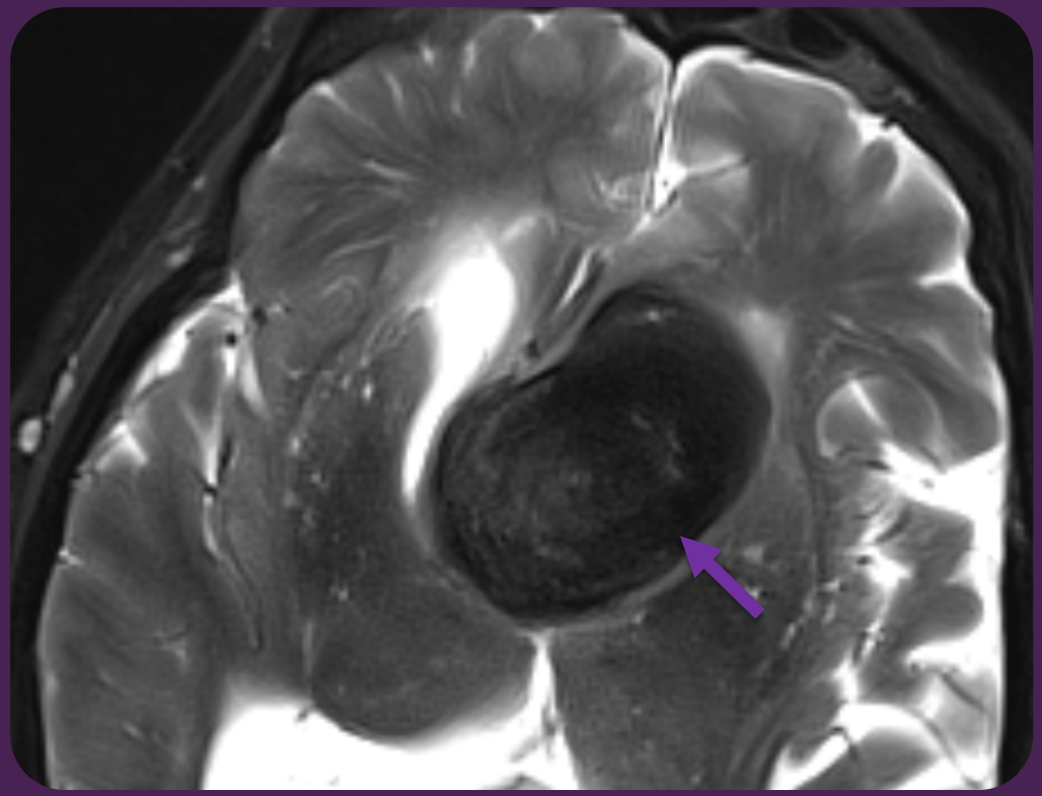

Internal T2 hypointense signal

Tumor or **aneurysm**?

CASE 4 · FIRST IMPRESSIONS

A calcified mass with hydrocephalus

FIRST LOOK · CT

Looks like a

calcified tumor

calcified meningioma vs craniopharyngioma

SECOND LOOK · MRI

T1-bright, T2-dark, susceptibility = internal thrombus

→ a giant **thrombosed aneurysm**

The trap: a giant thrombosed aneurysm can peripherally calcify and mimic a tumor — and here it presented due to mass effect, not bleeding.

CASE 4 · THE WORKUP

From anatomy to physiology

MRI — Giant ICA lesion, internal thrombus, mass effect + hydrocephalus
tumor vs aneurysm

CTA — Thrombosed aneurysm off the left ICA; patent neck fills with contrast
arises from the ICA

DSA — Giant ophthalmic-segment ICA aneurysm; filling of the neck
DSA-confirmed — fills off the ICA, not a tumor

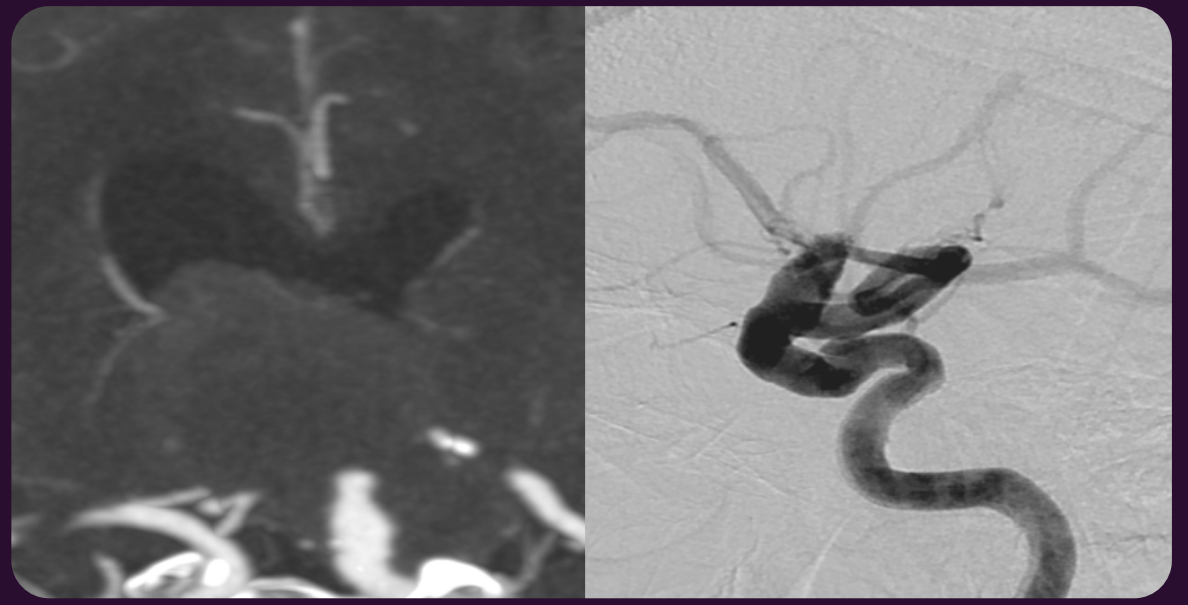

Diagnosis: **Giant thrombosed ophthalmic-segment ICA aneurysm** (~4.4 cm)

How we excluded tumor: a calcified tumor has no patent lumen → this mass filled from the ICA .

CASE 4 · MANAGEMENT

Shunt first, then the flow-diverter

- **Treat the hydrocephalus first** → VP shunt placement
- **Then secure the aneurysm** → Pipeline flow-diverter
  - needs dual antiplatelets (aspirin + ticagrelor) first
- Staging delayed by a shunt-tract hemorrhage
  - → held antiplatelets, then flow-diverted weeks later
- Raymond II occlusion → discharged, NSGY follow-up

TEACHING POINT

A giant thrombosed aneurysm can peripherally calcify and mimic a calcified brain tumor.

Here it presented with mass effect and hydrocephalus → not due to hemorrhage.

Treatment is **CSF diversion** first, then flow diversion of the aneurysm.

CASE 5

Gait imbalance — a posterior-fossa mass

Tumor vs Aneurysm · Five-case neuroradiology exhibit

CASE 5 · THE CASE

Gait imbalance → a posterior fossa mass

- **18-year-old female with no past medical history**
- **Presented for evaluation of worsening gait imbalance**
- Exam: Broad-based, ataxic gait
- No headache or infectious symptoms
- CT: Hyperattenuating midline posterior fossa mass

FIRST IMAGING — NON-CONTRAST CT

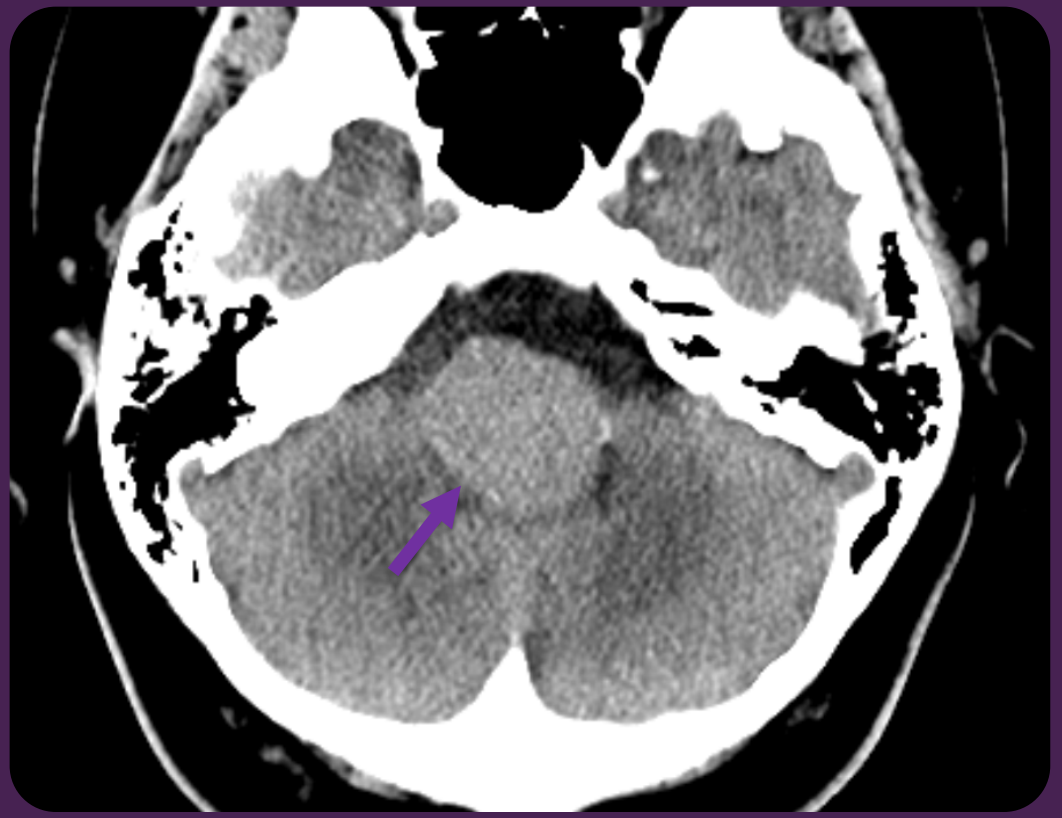

Hyperattenuating midline posterior fossa mass

Tumor or **aneurysm**?

CASE 5 · THE CASE

Gait imbalance → a posterior fossa mass

- **18-year-old female with no past medical history**
- **Presented for evaluation of worsening gait imbalance**
- Exam: Broad-based, ataxic gait
- No headache or infectious symptoms
- CTA: arterial enhancement with connection to the vertebrobasilar junction

SECOND IMAGING — CTA

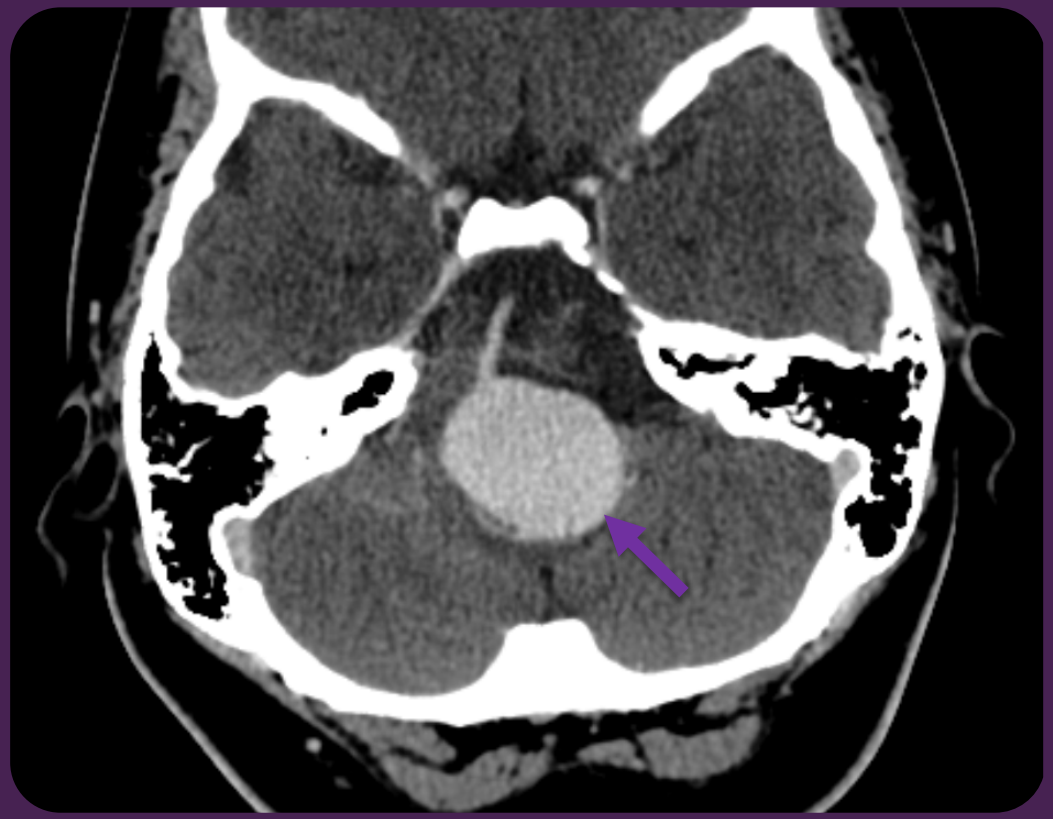

Avid arterial enhancement, connection to vertebrobasilar junction

Tumor or **aneurysm**?

CASE 5 · FIRST IMPRESSIONS

A large aneurysm with mass effect

FIRST LOOK · CT

Looks like a

hypercellular tumor

Medulloblastoma vs lymphoma

SECOND LOOK · CTA

Arterially enhancing lesion arising from the vertebrobasilar junction

→ a giant **aneurysm**

The trap: a giant thrombosed aneurysm can mimic a hypercellular tumor. Large aneurysms can become symptomatic due to mass effect, even without rupture.

CASE 5 · THE WORKUP

From anatomy to physiology

CTA

Thrombosed aneurysm off the vertebrobasilar junction; patent lumen fills

›

DSA

Giant vertebrobasilar aneurysm filling from the vertebrobasilar junction → not a tumor.

›

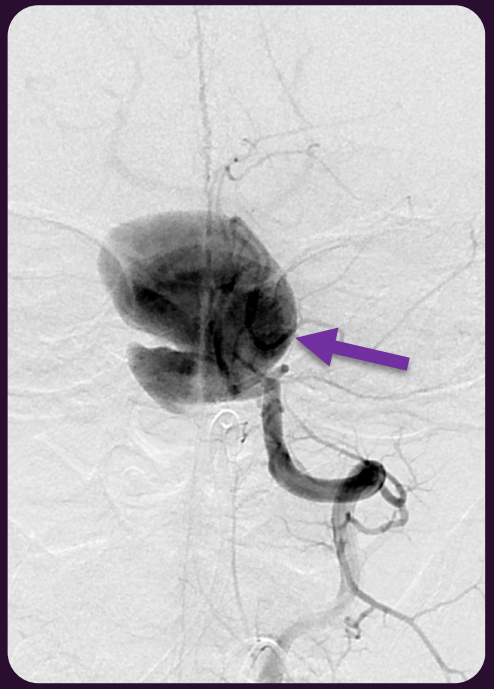

Diagnosis: **Giant vertebrobasilar aneurysm** (~3.5 cm)

How we excluded tumor: CTA and DSA confirm communication with the parent artery

CASE 5 · MANAGEMENT

Turn off the faucet, but not too fast

- **Gradually decrease flow**
- **Coil occlusion (sacrifice) of the left vertebral artery**
- Test balloon occlusion of the right vertebral artery, then coil occlusion

  → aneurysm now only fills from the posterior communicating arteries, and should have a lower risk for growth and rupture

TEACHING POINT

A giant thrombosed aneurysm can mimic a hypercellular brain tumor.

Here it presented due to mass effect → not hemorrhage.

Treatment is flow diversion of the aneurysm when possible.

KEY LEARNING POINTS

Five cases, five takeaways

CASE 1

A vascular posterior-fossa lesion abutting an artery is the classic tumor-vs-aneurysm dilemma. Enhancement pattern + DSA differentiate it.
Be suspicious of an “aneurysm” with adjacent parenchymal edema.

CASE 2

A partially thrombosed cavernous aneurysm is a classic meningioma mimic. Layered-thrombus signal + a lumen continuous with the carotid flip the diagnosis. Treatment is endovascular flow diversion.

CASE 3

An enhancing nodule inside a spinal hematoma can mimic a hemorrhagic tumor. Get catheter angiography before calling it neoplasm. Open evacuation when the aneurysm can’t be reached endovascularly.

CASE 4

A giant thrombosed aneurysm can calcify and mimic a calcified brain tumor. Large aneurysms sometimes present due to mass effect instead of hemorrhage. CSF diversion first, then flow diversion.

CASE 5

A giant fusiform vertebrobasilar aneurysm can present like a hyperdense posterior-fossa tumor. CTA proves the parent-vessel connection. Staged vessel sacrifice can reduce flow when clip / stent isn’t feasible.

Beware of the “mass” with:

- Peripheral calcification
- Pulsation artifact (MRI)
- Marked T2 hypointensity
- Enhancement matching arteries

Beware of the “aneurysm” with adjacent parenchymal edema