

Meningitis Secondary to a Sacral Decubitus Ulcer with Fistulization to the Spinal Canal

Brandon Huddleston BS¹, Isaiah Edwards BS¹, Nicholas Turner MD¹,
Charlotte S. Taylor MD¹

University of Mississippi Medical Center, Department of Radiology¹

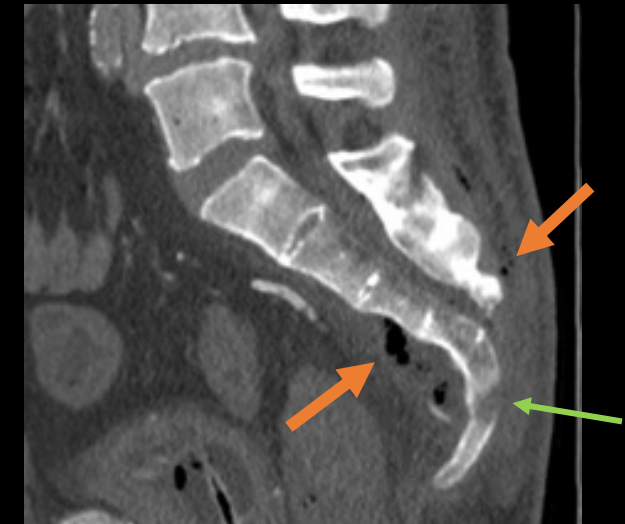
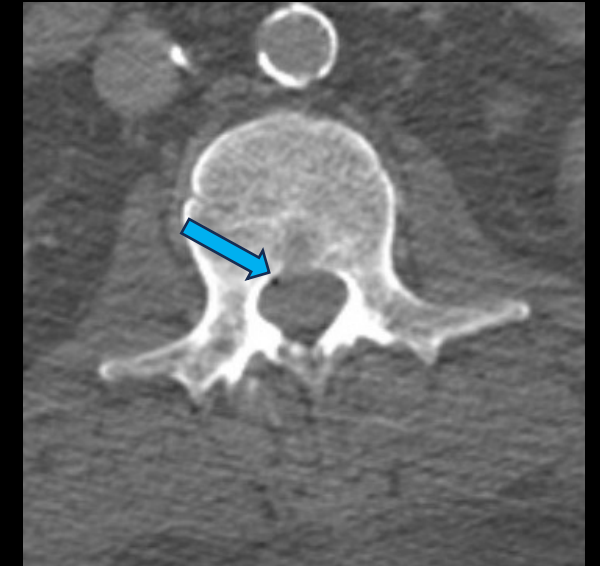
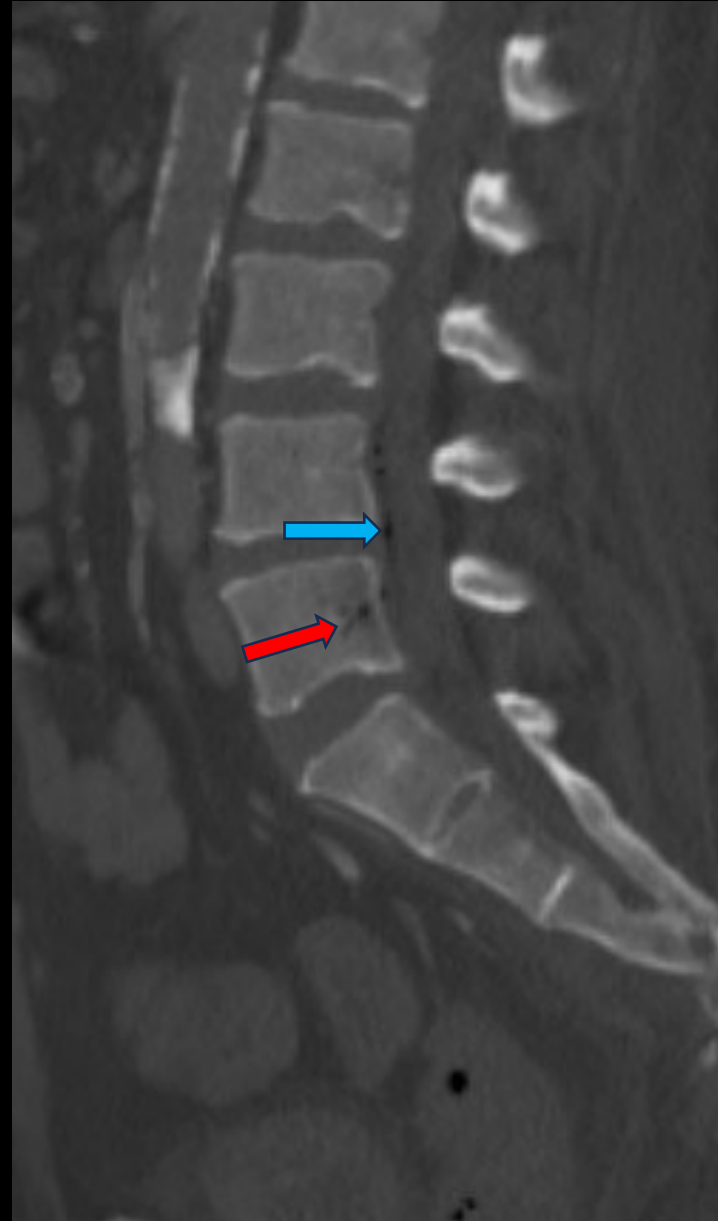

Clinical Presentation

- 40-year-old male wheelchair-bound presenting with altered mental status and seizure, also with a stage 4 sacral pressure ulcer

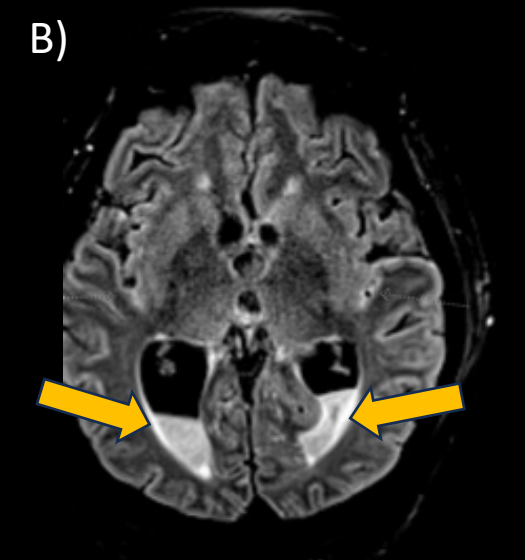
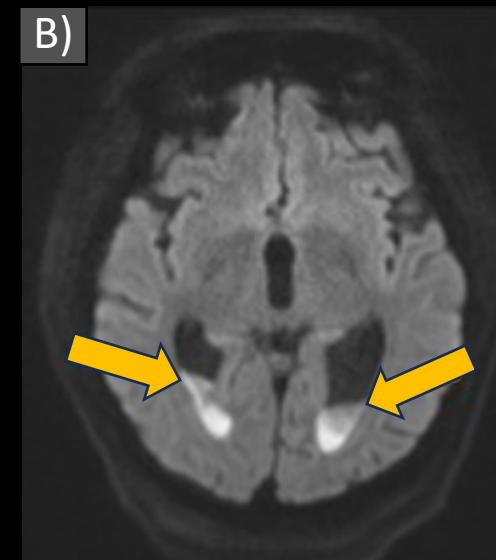
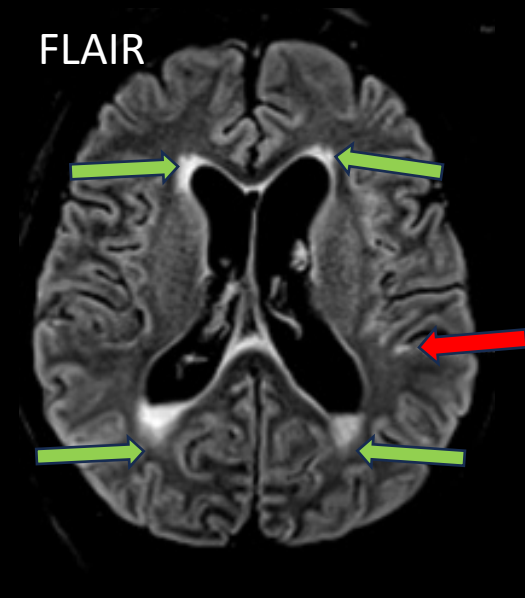
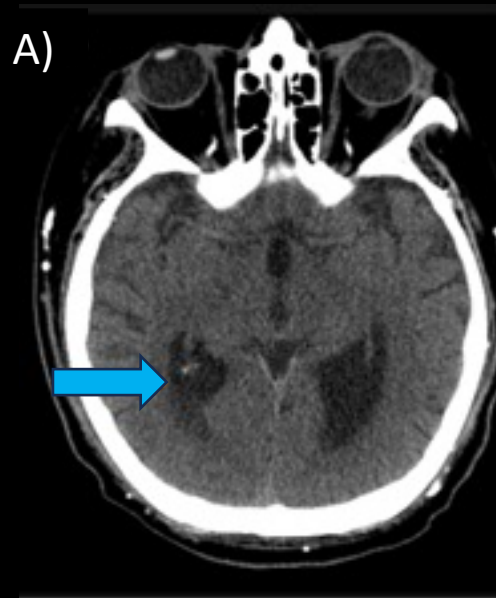
Imaging Workup

- CT CAP: Large sacral decubitus ulcer with multiple foci of gas in the gluteal soft tissues and the presacral space, sacral bone erosion, a collection of gas within the posterior aspect of the L5 vertebrae concerning for osteomyelitis, and multiple foci of gas within the spinal canal at the thoracic and lumbar levels



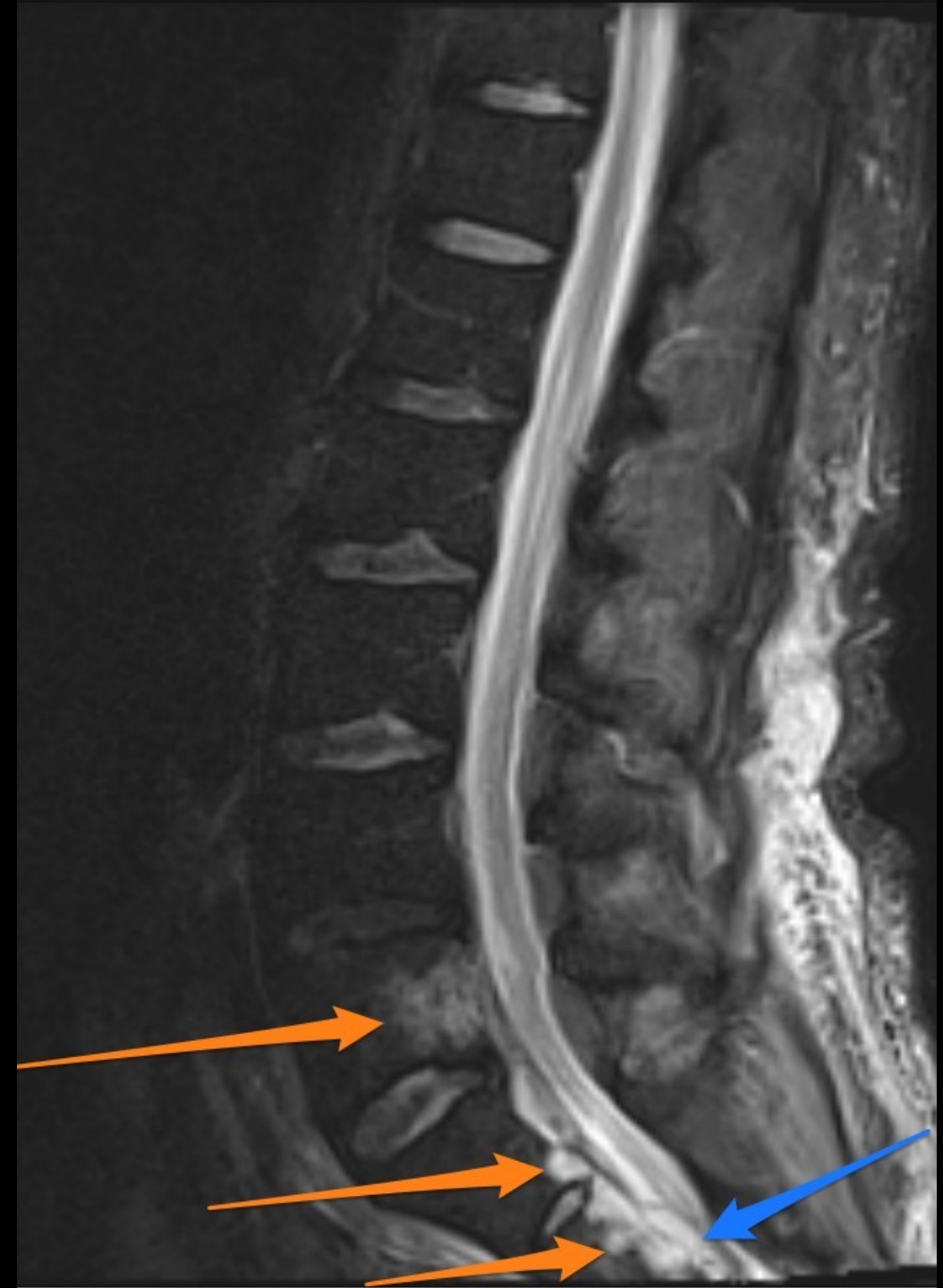Imaging Workup

- Axial CT head: **Small volume isodense material in the bilateral occipital horn, likely representing infected debris, and mild hydrocephalus**
- Axial MRI brain: **Layering complex fluid in the posterior horns of the lateral ventricle with diffusion restriction of the fluid, small scattered complex fluid in the sulci of the bilateral temporoparietal lobes and the sylvian fissures, and T2/FLAIR hyperintense signal in the periventricular white matter concerning for transependymal edema in the setting of acute hydrocephalus**



Imaging Workup

- MRI lumbar spine showed abnormal STIR hyperintense marrow signal in the **posterior sacral bodies and the L5 vertebra** and a **ventral sacral epidural collection**, and diffuse abnormal enhancement of the cauda equina nerve roots



Management

- Based on patient imaging and clinical presentation a diagnosis of meningitis and sepsis secondary to sacral ulcer tracking into the spinal canal and osteomyelitis of the coccyx was made
- An external ventricular drain was placed by neurosurgery
- The patient underwent sacral ulcer debridement with deep wound and blood cultures growing *E. coli*
- The patient was treated with ceftazidime for 6 weeks for management of osteomyelitis and sepsis

Outcome

With improvement of hydrocephalus on CT head and no further signs of encephalopathy or systemic infection, the patient was discharged to a long-term care facility.

Take Home Points

- Sacral ulcers resulting in communication with the spinal canal and causing meningitis are extremely rare occurrences, with only a few cases documented.
- Patients with a sacral pressure injury that communicates with the spinal canal often present with encephalopathy, seizures, and signs of systemic infection.
- This case represents a rare underlying cause of meningitis with a rare imaging finding of pneumorachis, and it is our hope that this encourages physicians to consider all sources of infection for encephalopathic patients with MRI imaging suggestive of meningitis.
- Our case demonstrates one of the many complications associated with pressure injuries and emphasizes the importance of primary prevention and rapid, proper wound care of sacral injuries.

References

- Miyaji Y, Kurokawa T, Tanaka F, Koyama K. Meningitis with pneumocephalus originating from a sacral pressure ulcer. *Intern Med*. 2013;52(18):2163-4. doi: 10.2169/internalmedicine.52.0935. PMID: 24042536.
- Willheim K, Jurjevic A, Tomic Z. Pneumocephalus as a complication of metastases and eroding infection in the sacral region. *J Neurol Neurosurg Psychiatry*. 1998 Jan;64(1):136-7. doi: 10.1136/jnnp.64.1.136. PMID: 9436747; PMCID: PMC2169921.