

Overlooked Adenoid Cystic Carcinoma of Nasopharynx with Clivus Invasion

Tuba Kalelioglu, MD

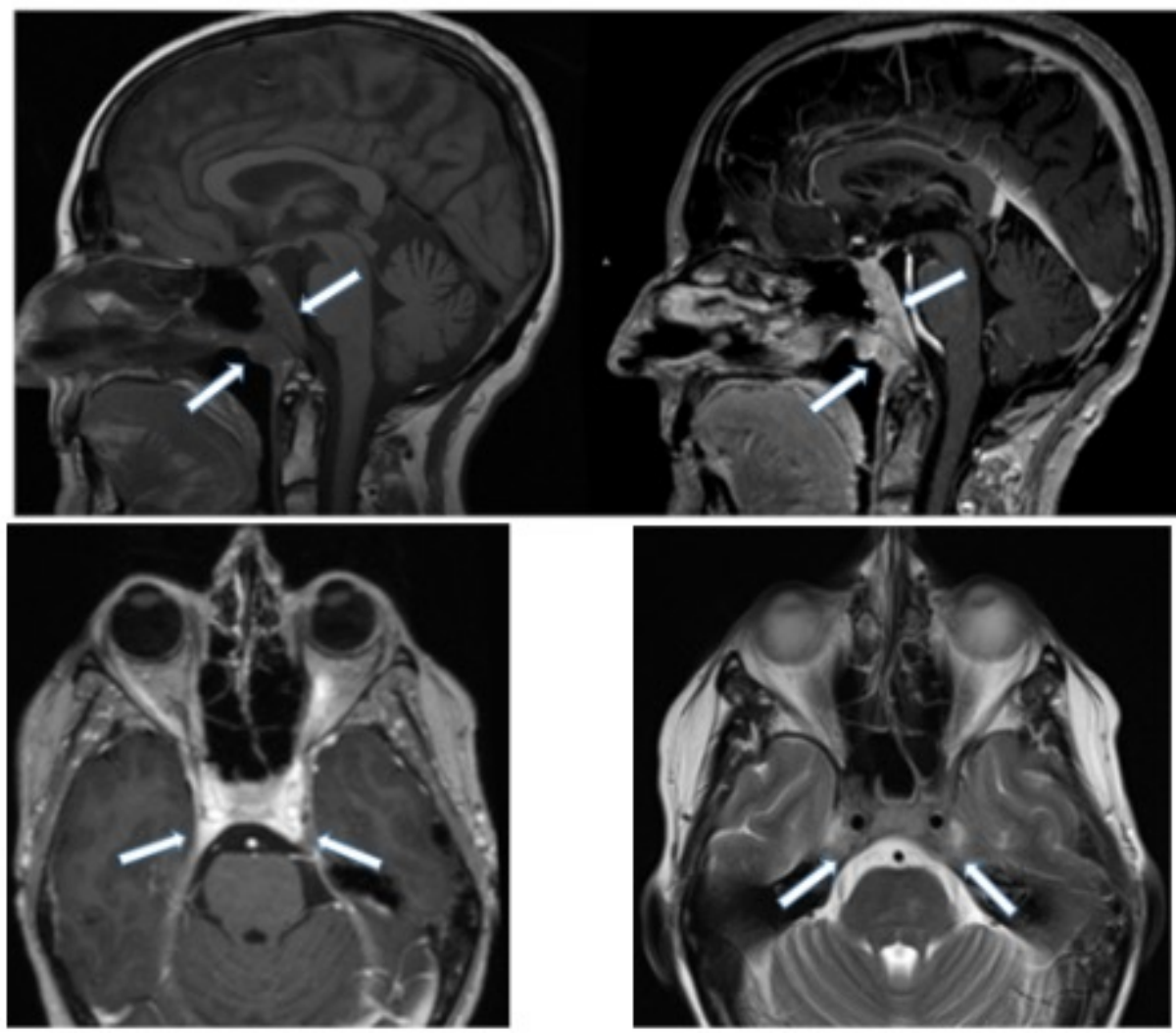


UNIVERSITY
of
VIRGINIA

Clinical Presentation

- A 66 year old male presented to ED with diplopia. Neurologic exam revealed bilateral 6th nerve palsy.

Imaging Discussion



- MRI brain showed T1 hypointense, T2 isointense enhancing lesion involving clivus and bilateral cavernous sinuses. Unfortunately, imaging findings were overlooked on first interpretation but appreciated on second look with potential extension to nasopharynx. Patient underwent a nasopharynx biopsy. Pathology revealed adenoid cystic carcinoma of nasopharynx.

Management and Outcome

- Patient underwent chemoradiotherapy with progressive disease in 3 months.

Take Home Points

- Adenoid cystic carcinoma of nasopharynx is an uncommon malignancy with high local invasiveness and perineural tumor spread. Local invasion into clivus could represent itself as a primary clival lesion. It is important to pay attention to the clival marrow signal to not to overlook an infiltrating lesion. Non expansile clival lesion could be easily missed without paying attention to the T1 hyperintense bone marrow.

References

- Abdul-Hussein A, Morris PA, Markova T. An unusual presentation of adenoid cystic carcinoma of the minor salivary glands with cranial nerve palsy: a case study. BMC Cancer. 2007 Aug 13;7:157. doi: 10.1186/1471-2407-7-157. PMID: 17697321; PMCID: PMC1994955.